

Intervention in the neck - Biopsy techniques.

www.headandneckultrasound.co.uk


Rhodri M. Evans



Fine Needle or Core Biopsy?



- First line – cytology.
- If cytology can't give the answer – core biopsy.
- ?Lymphoma – core biopsy.



Needles – Ultrasound.



- Positioning.
- Equipment.
- Technique.










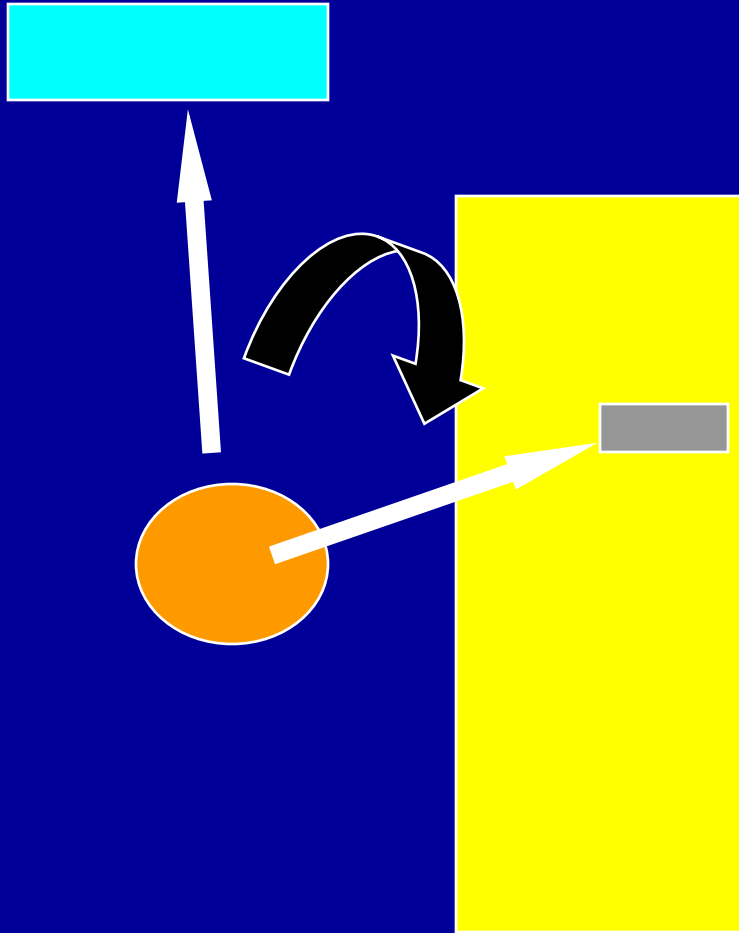



































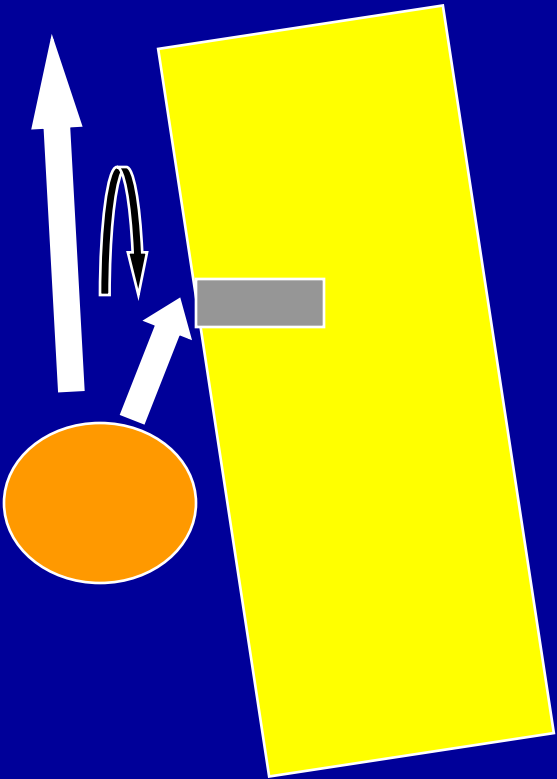











































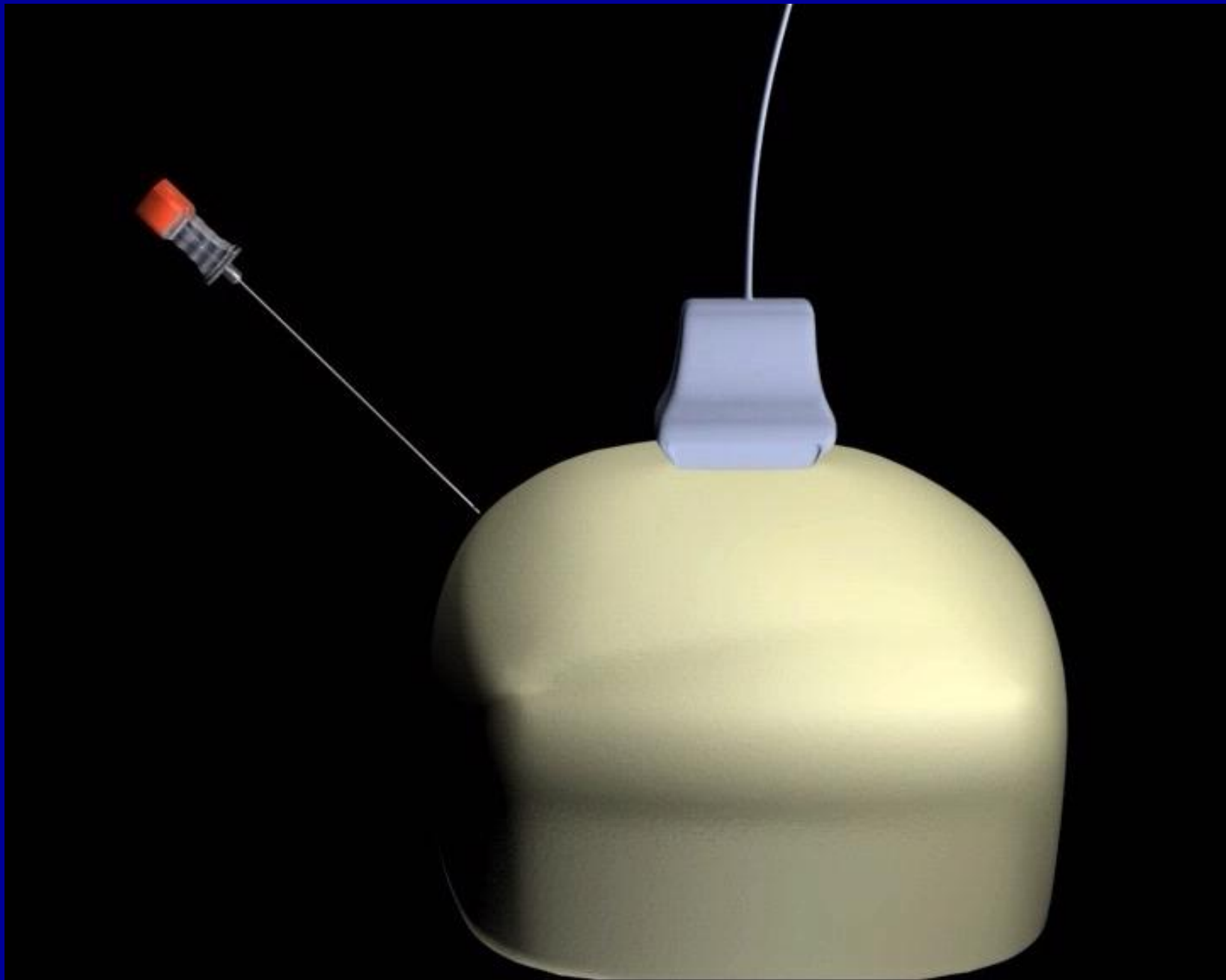


© Getty Images

Needles.

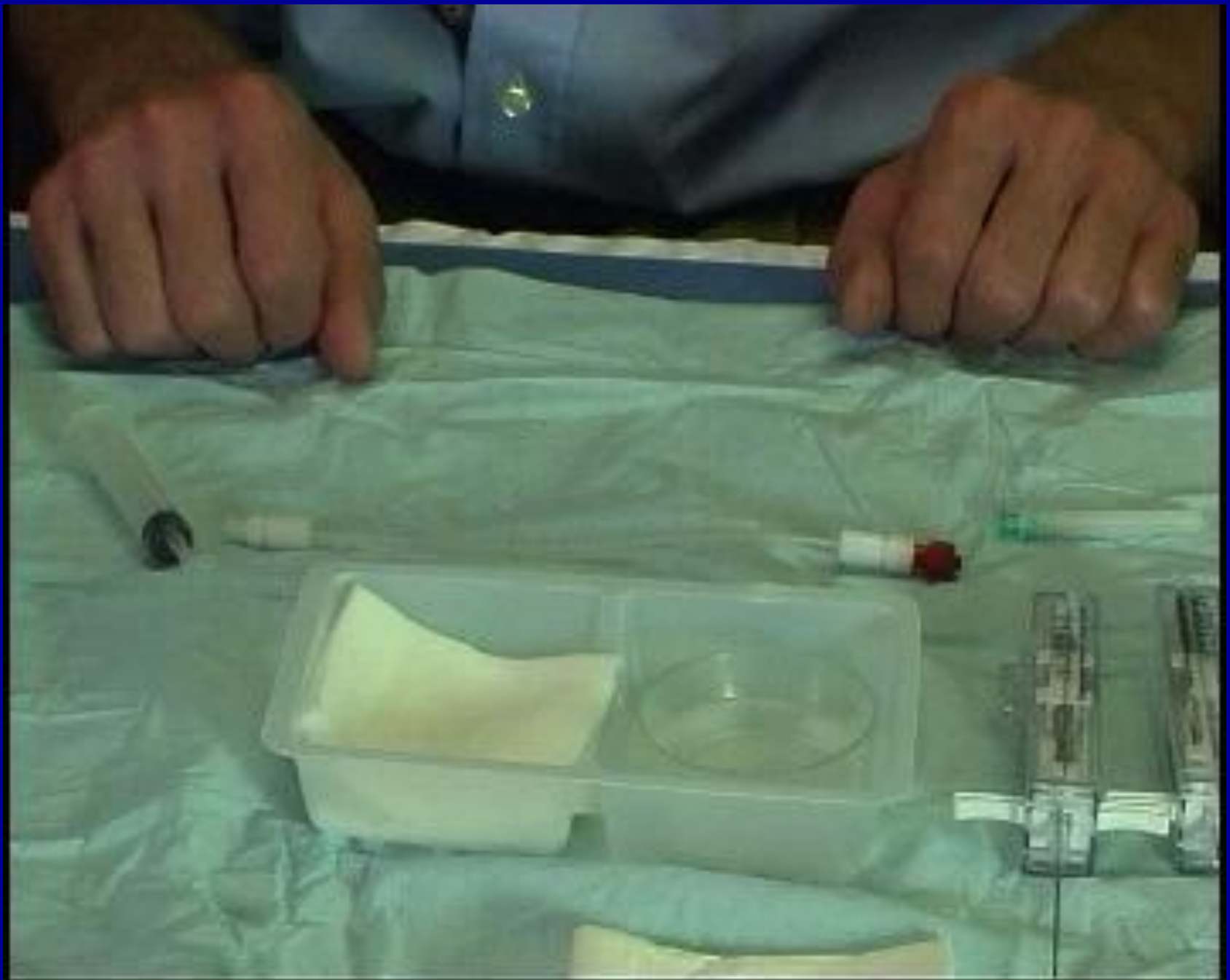- Positioning.
- Parallelism.





Needles.


- Positioning.
- Equipment.



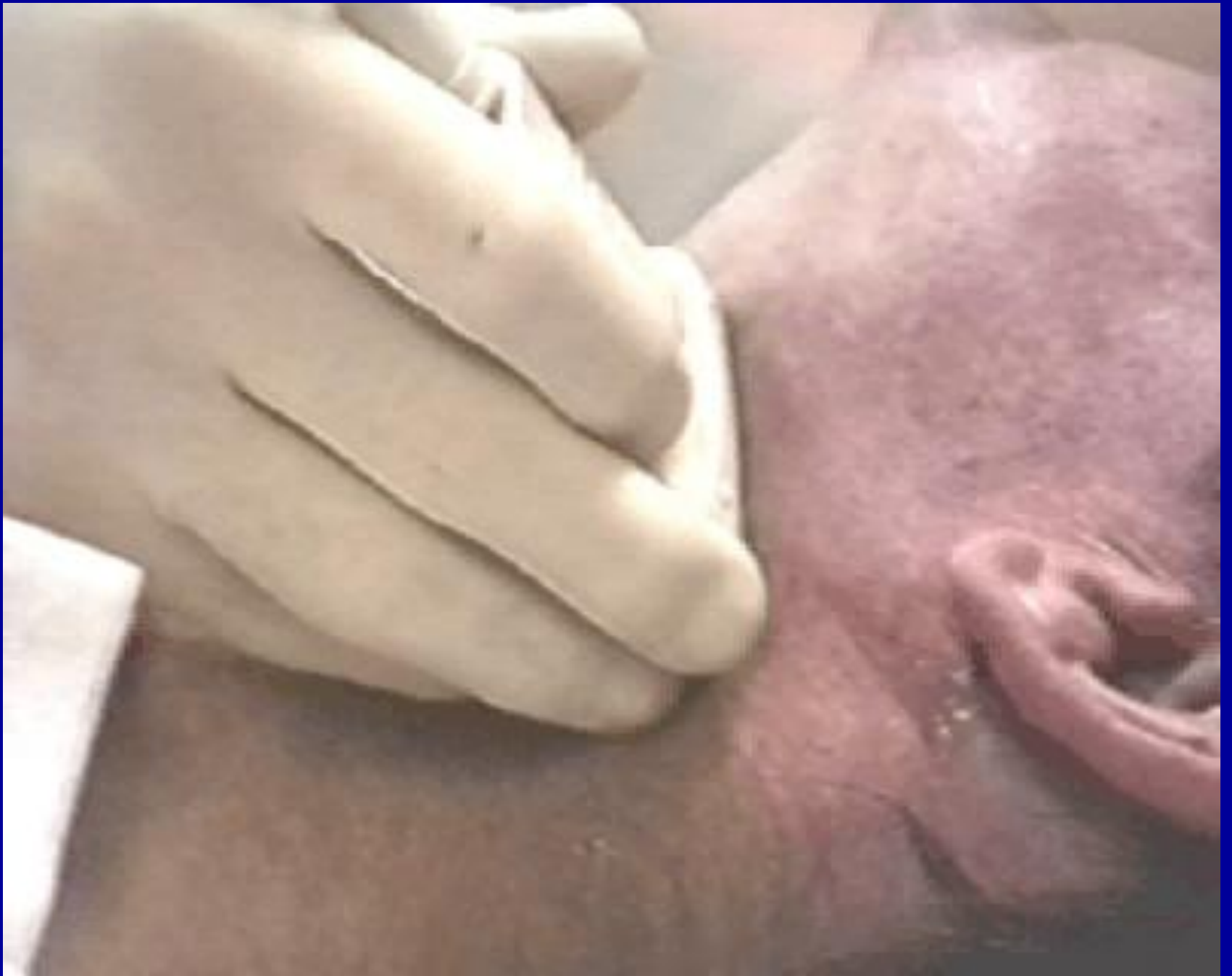Technique.

- Avoid contamination – cling film.
- Short axis approach.
- Rotation, rotation, rotation.
- Aspiration or no aspiration?
- Release pressure before withdrawal.
- Increase specimen yield – preparation.











Technique.







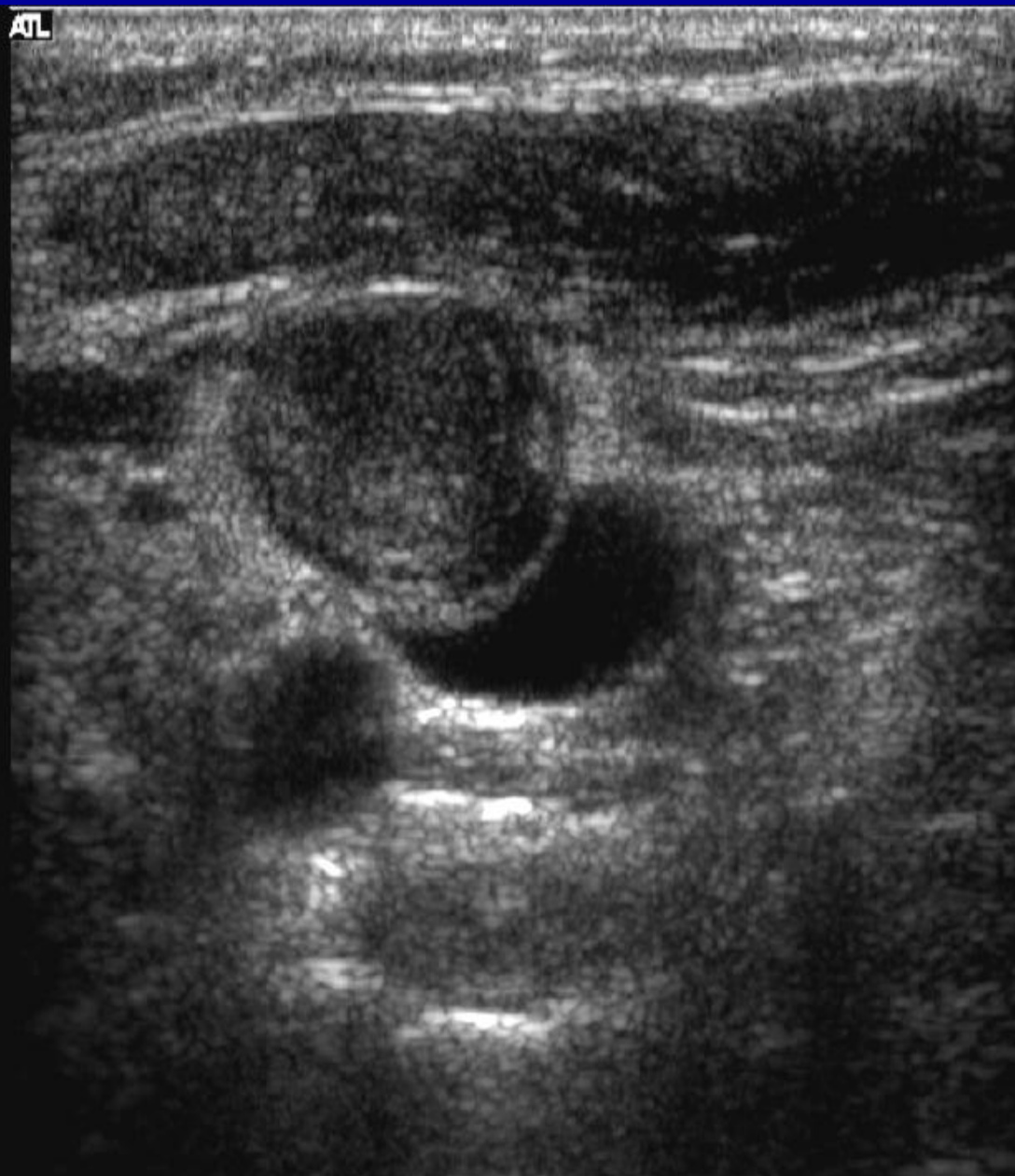



In practise?

- Knowledge
- Hand/eye coordination.
- Needle/probe.
- Needle/monitor.

Map 3
150dB/C 2
Persist Med
2D Opt:Res

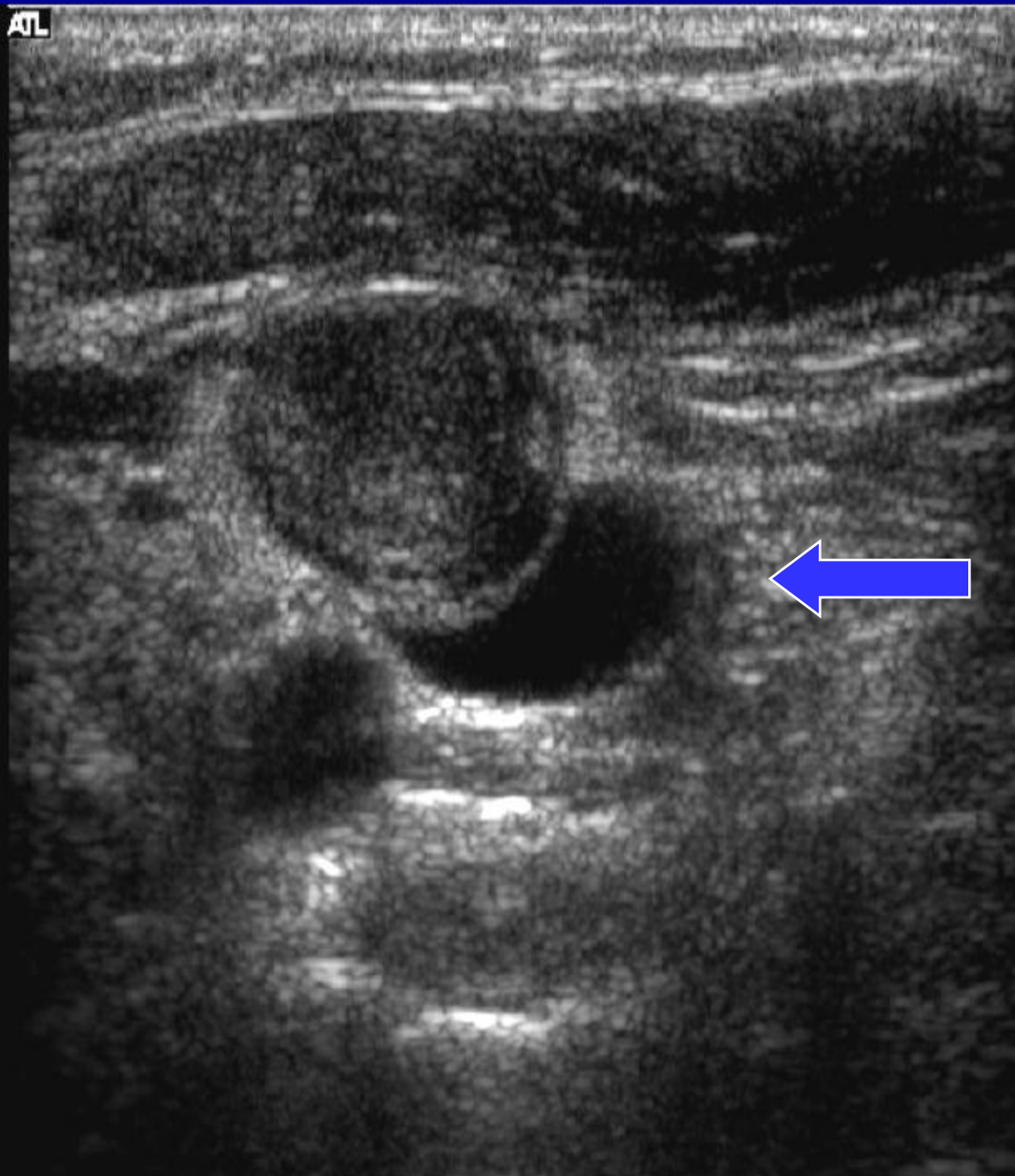


-1

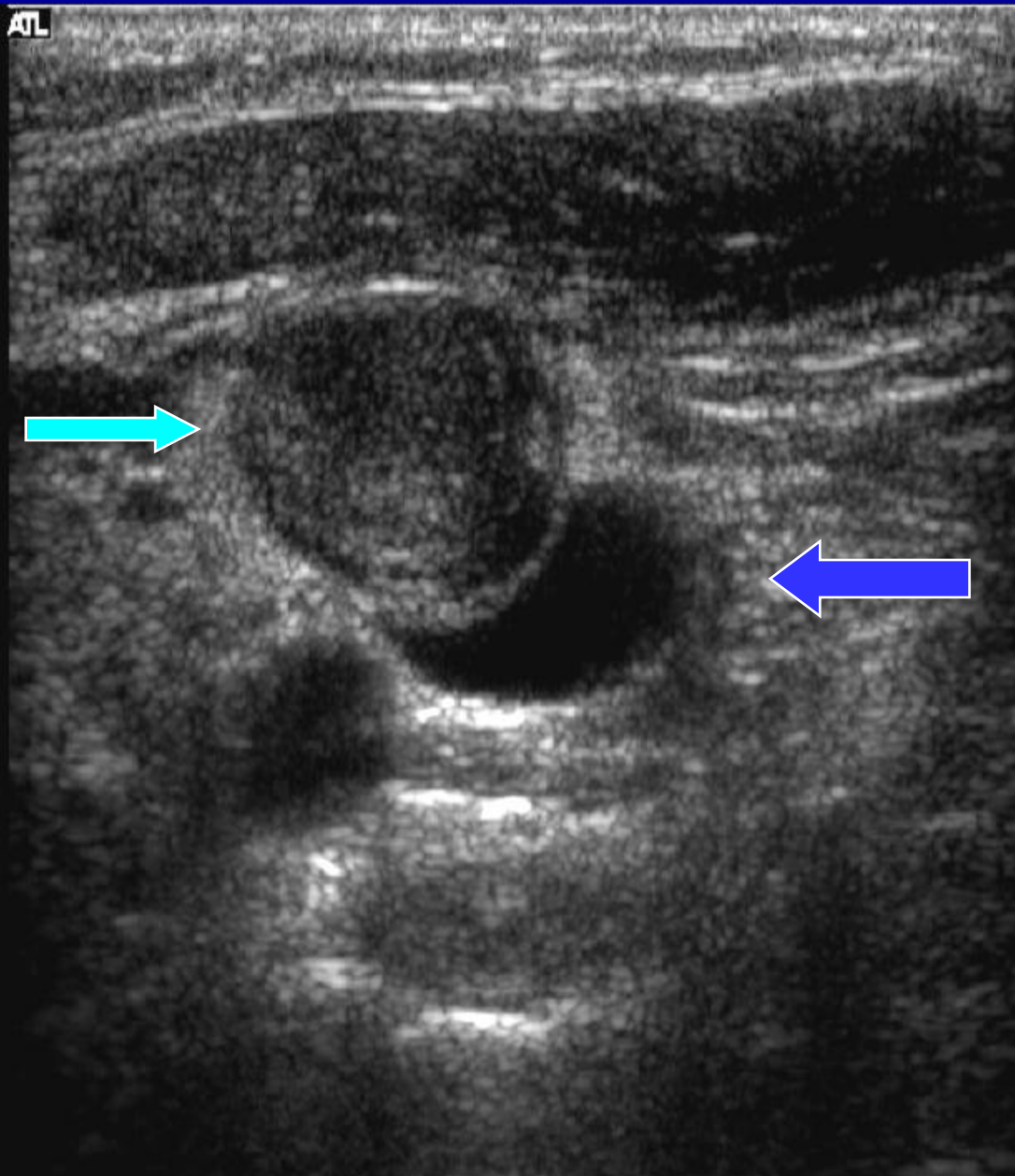
-2

-3

Map 3
150dB/C 2
Persist Med
2D Opt:Res



Map 3
150dB/C 2
Persist Med
2D Opt:Res



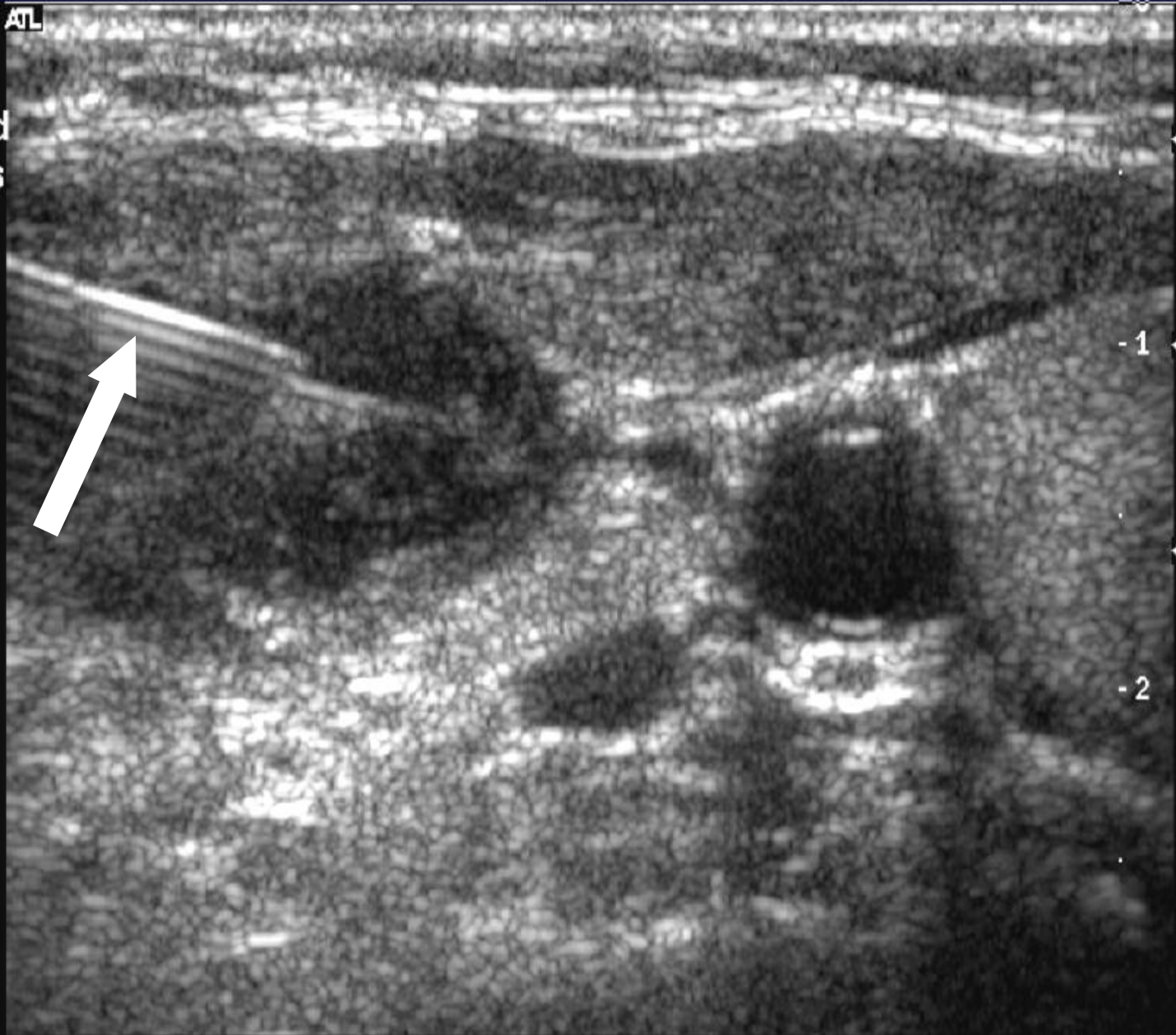
-1

-2


-3




Map 3
150dB/C 2
Persist Med
2D Opt:Res




Normal lymph nodes.



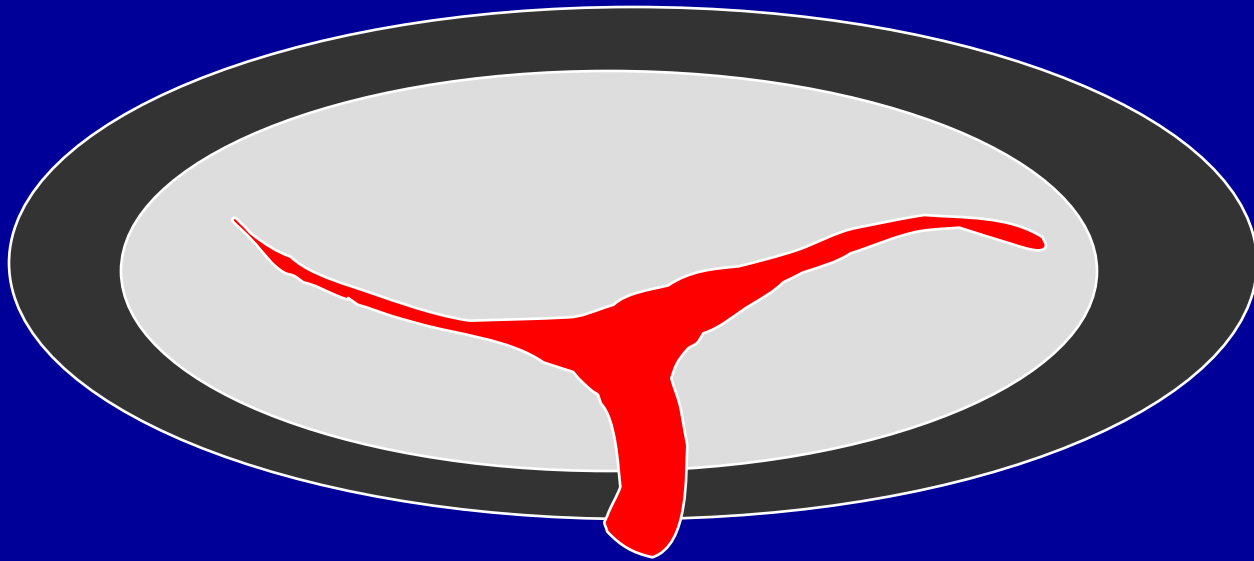
Normal lymph nodes.




Normal lymph nodes.




Normal lymph nodes.

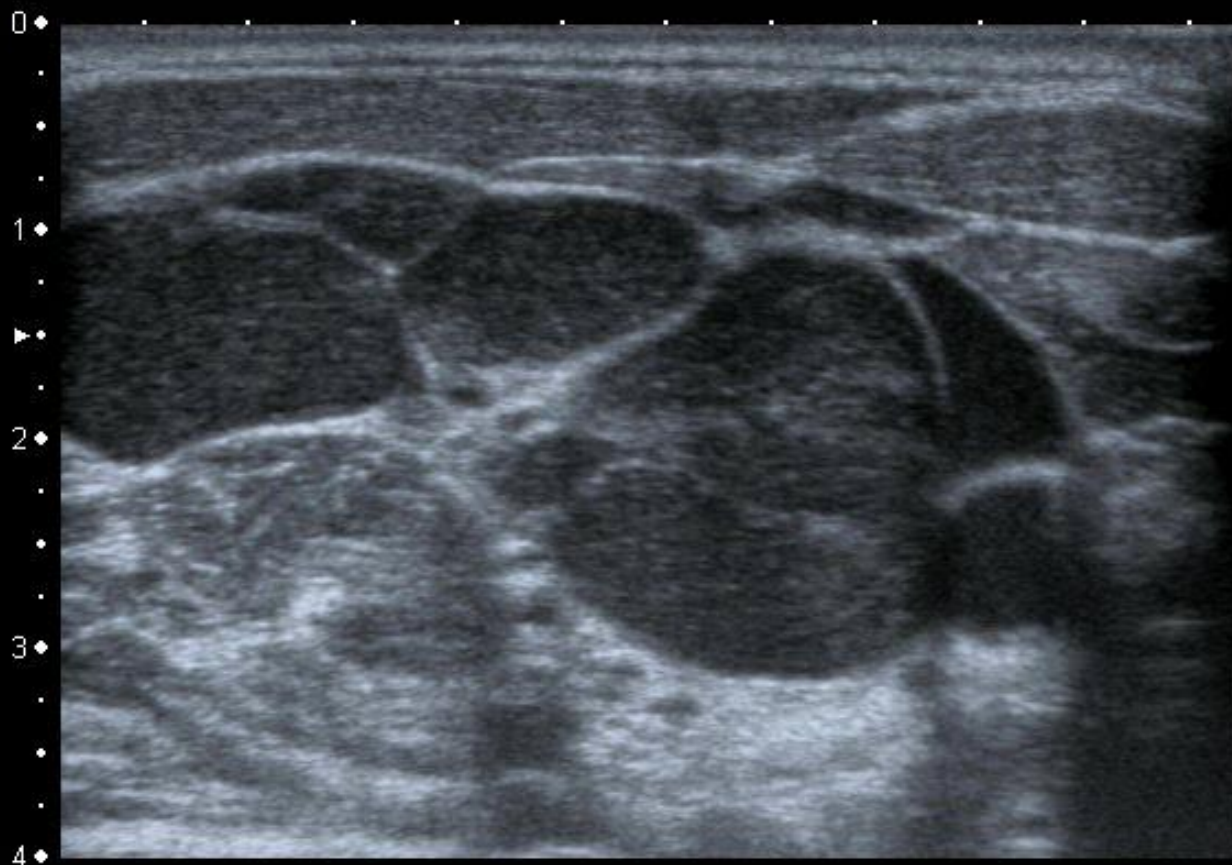


Lymphoma?



Lymphoma




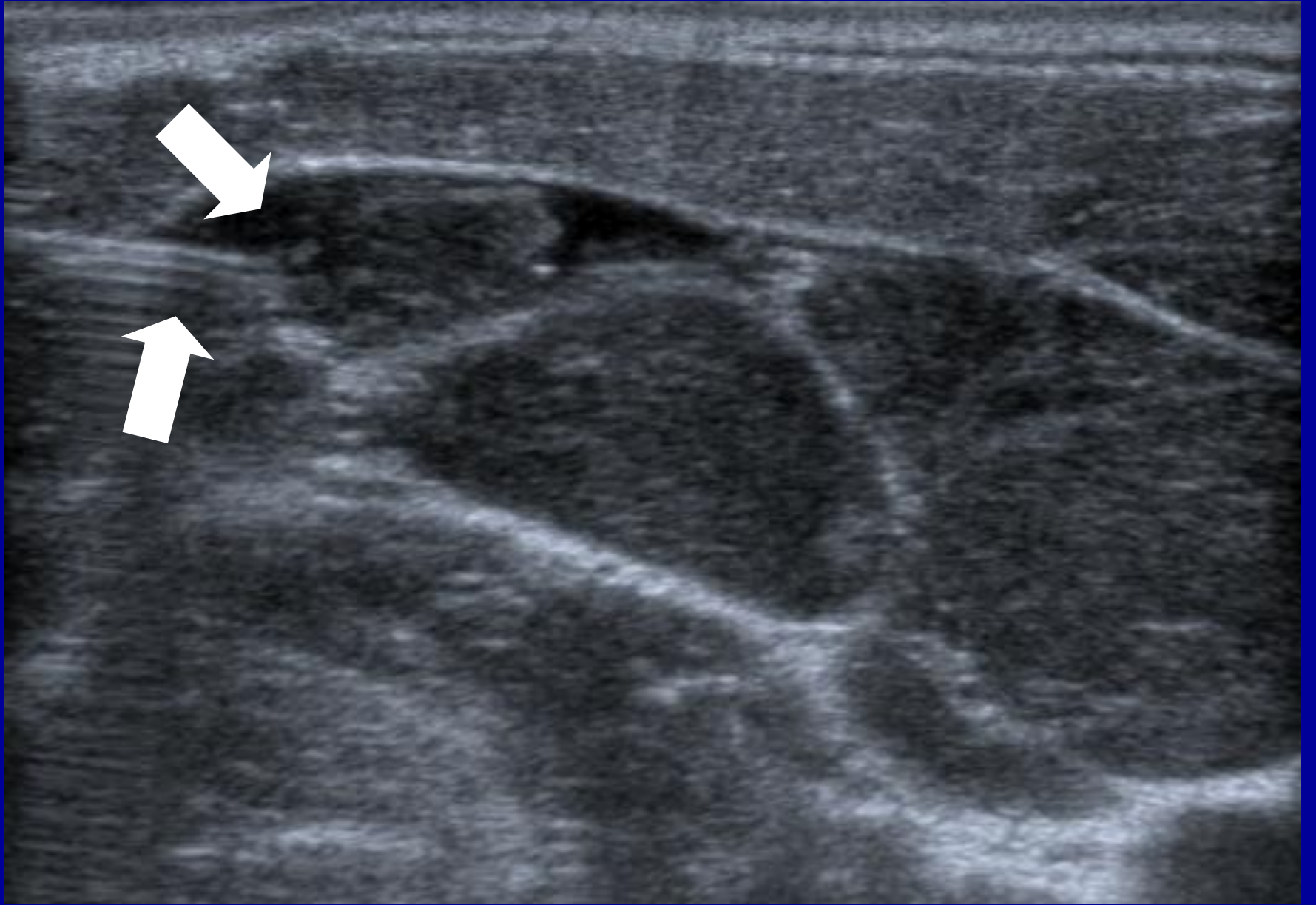


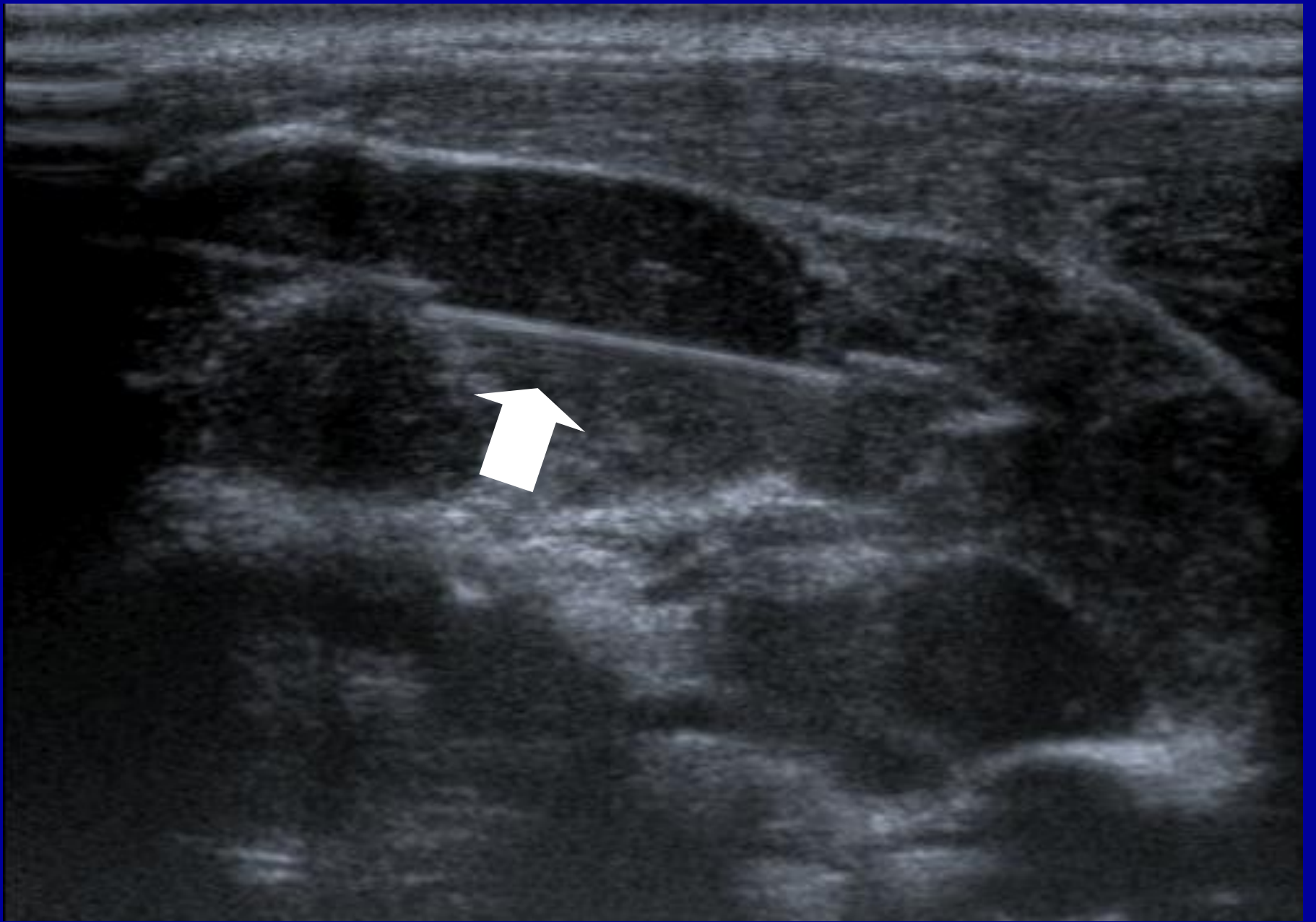
MI:1.6
2DG
80
DR
70

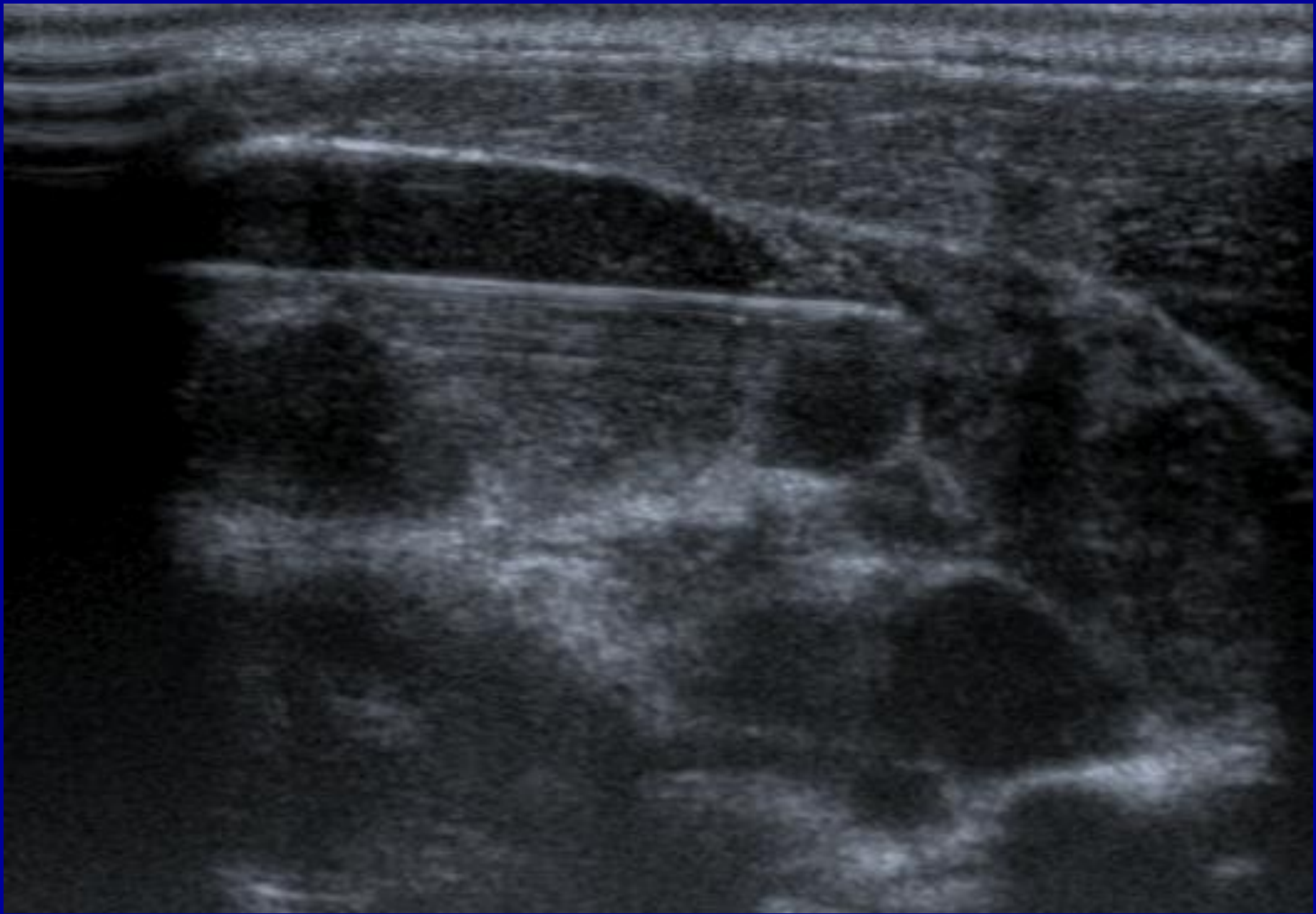
12L5
T9.0
33 fps

0 ◆
1 ◆
2 ◆
3 ◆
4 ◆












Metastatic lymph nodes



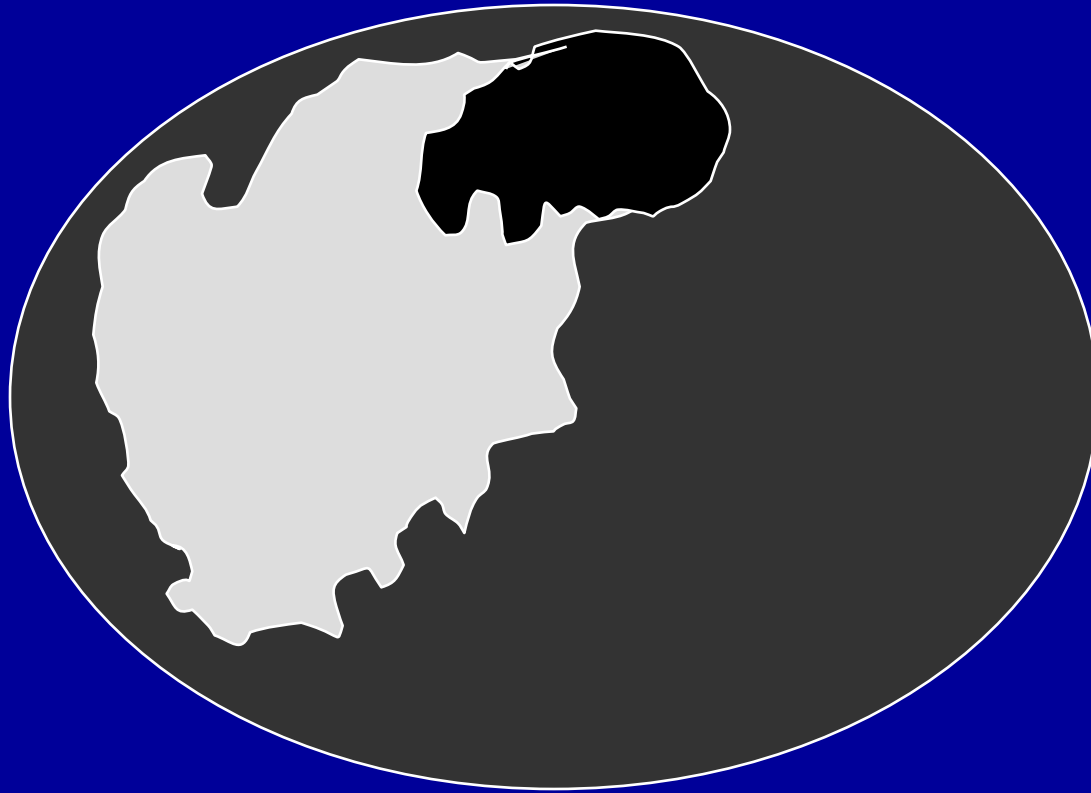
Malignant lymph nodes.



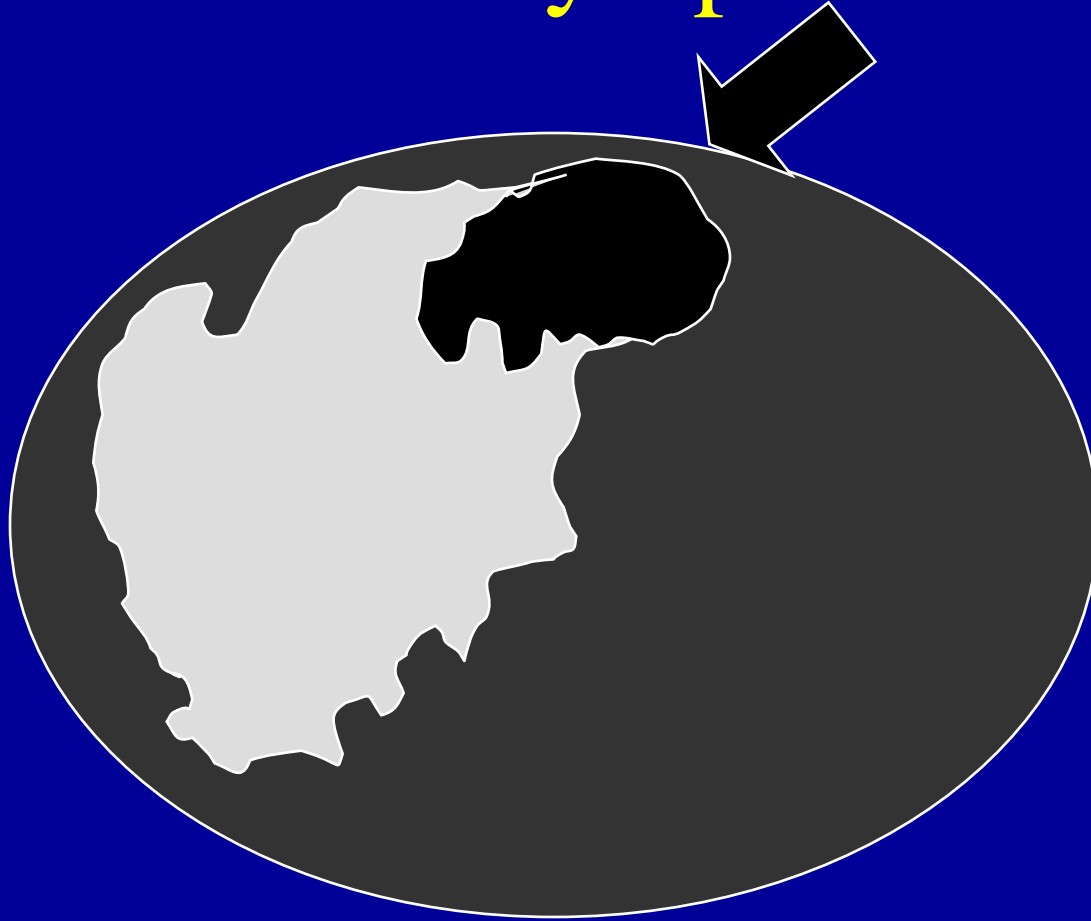
Metastatic lymph nodes

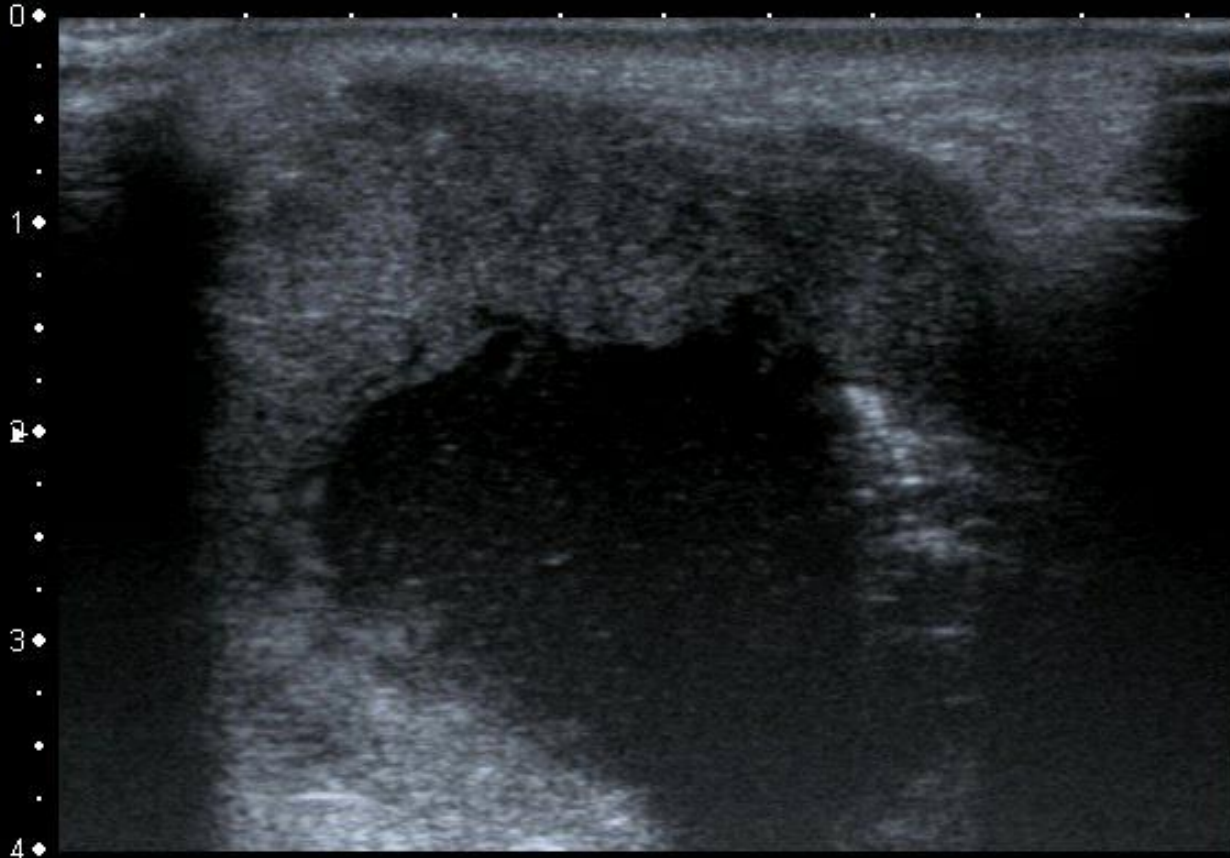


Metastatic lymph nodes



Metastatic lymph nodes




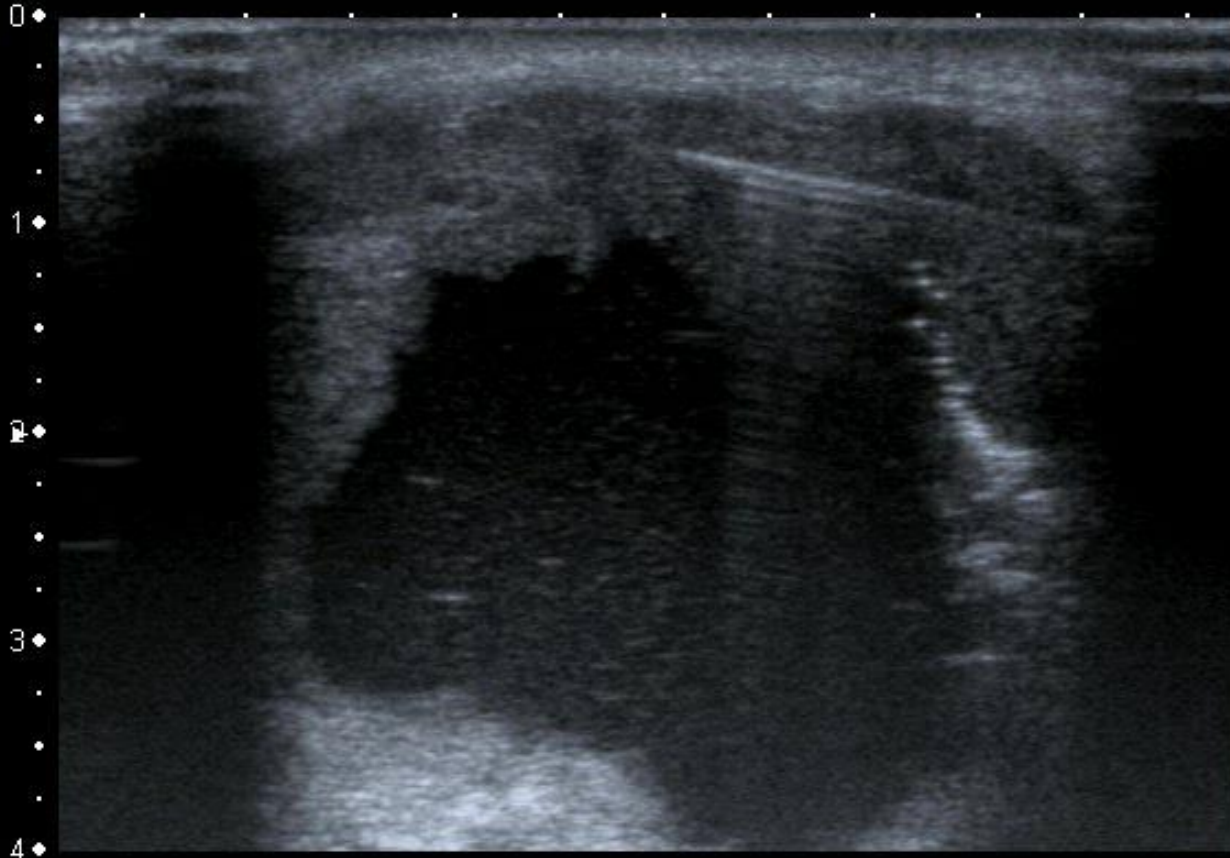


MI:1.6
2DG
85
DR
70

12L5
T9.0
37 fps


0 ♦
1 ♦
2 ♦
3 ♦
4 ♦






MI:1.6
2DG
85
DR
70

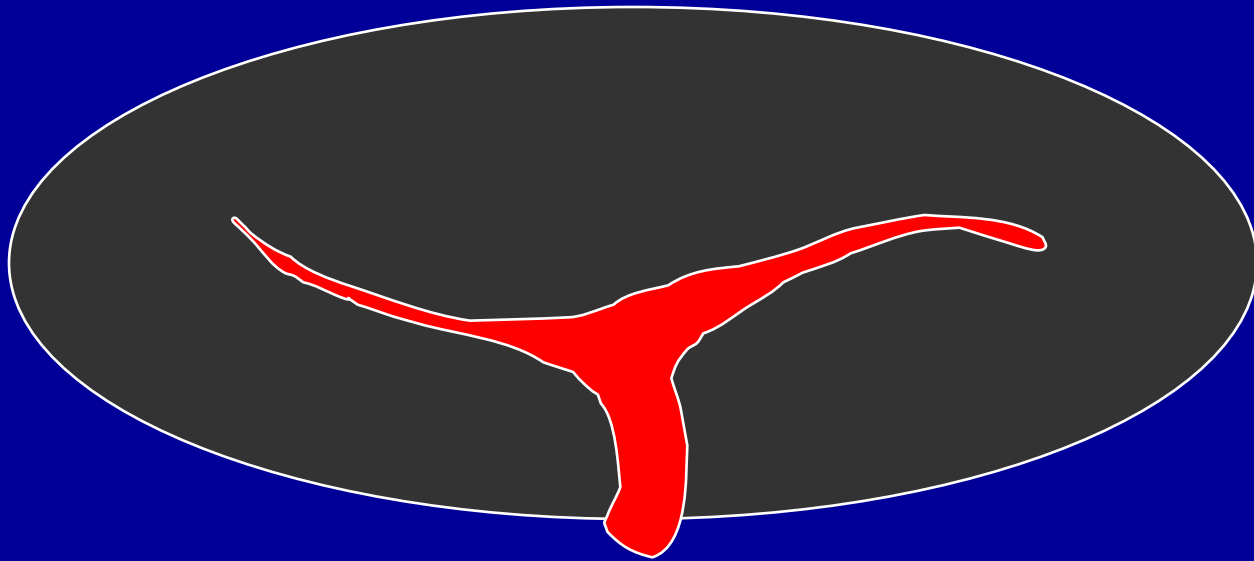
12L5
T9.0
37 fps




Normal lymph nodes.



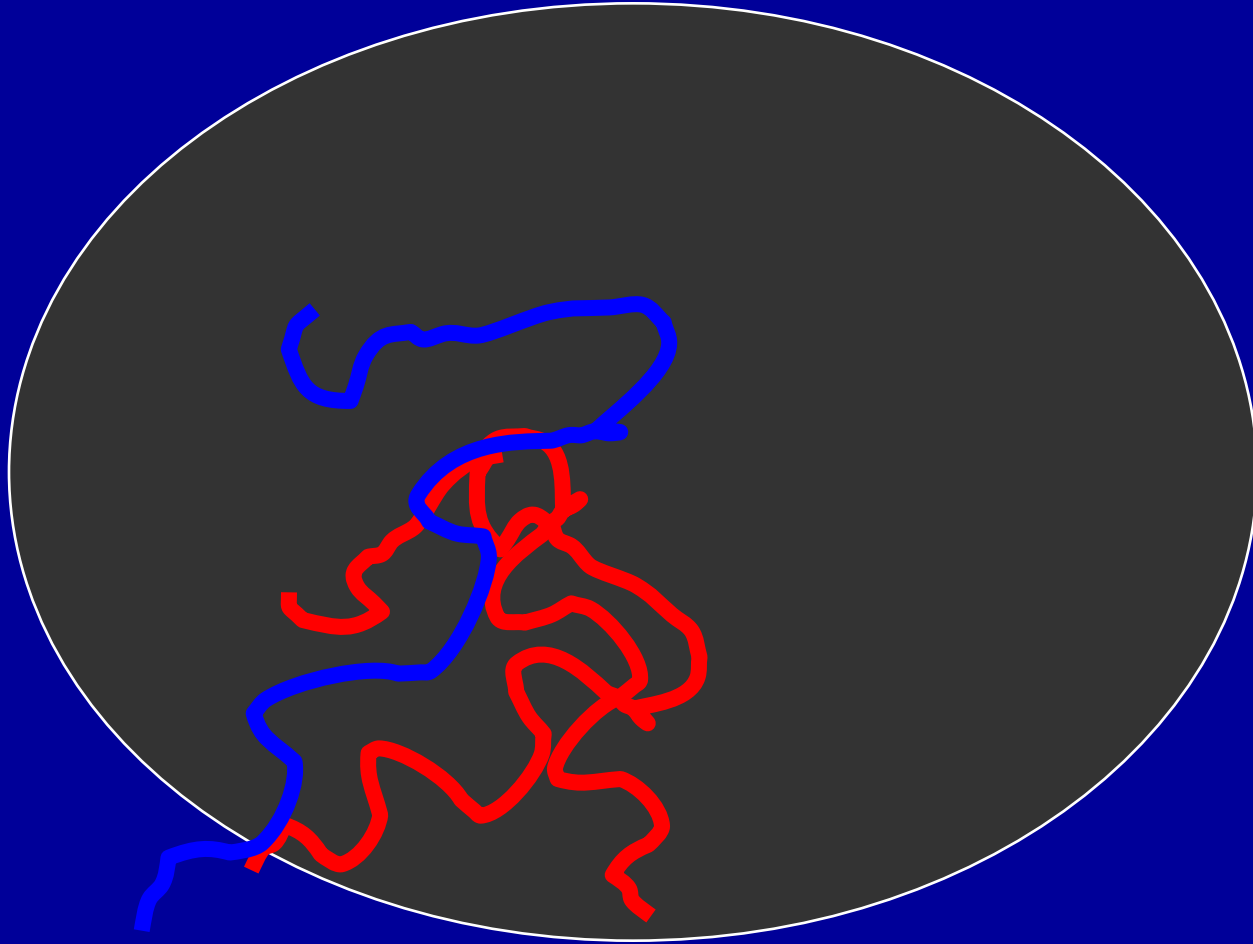
Normal lymph nodes.



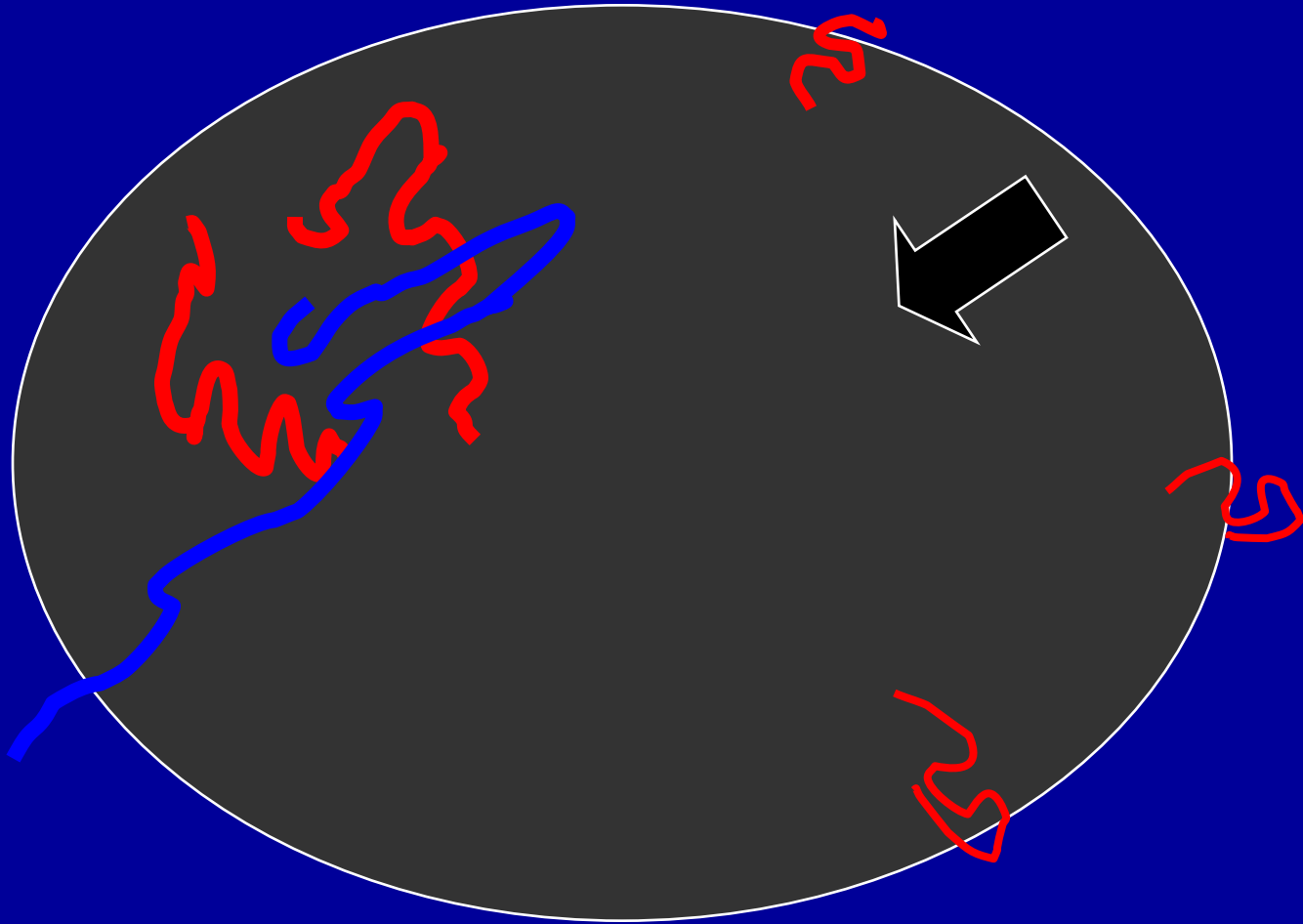
Malignant lymph nodes.



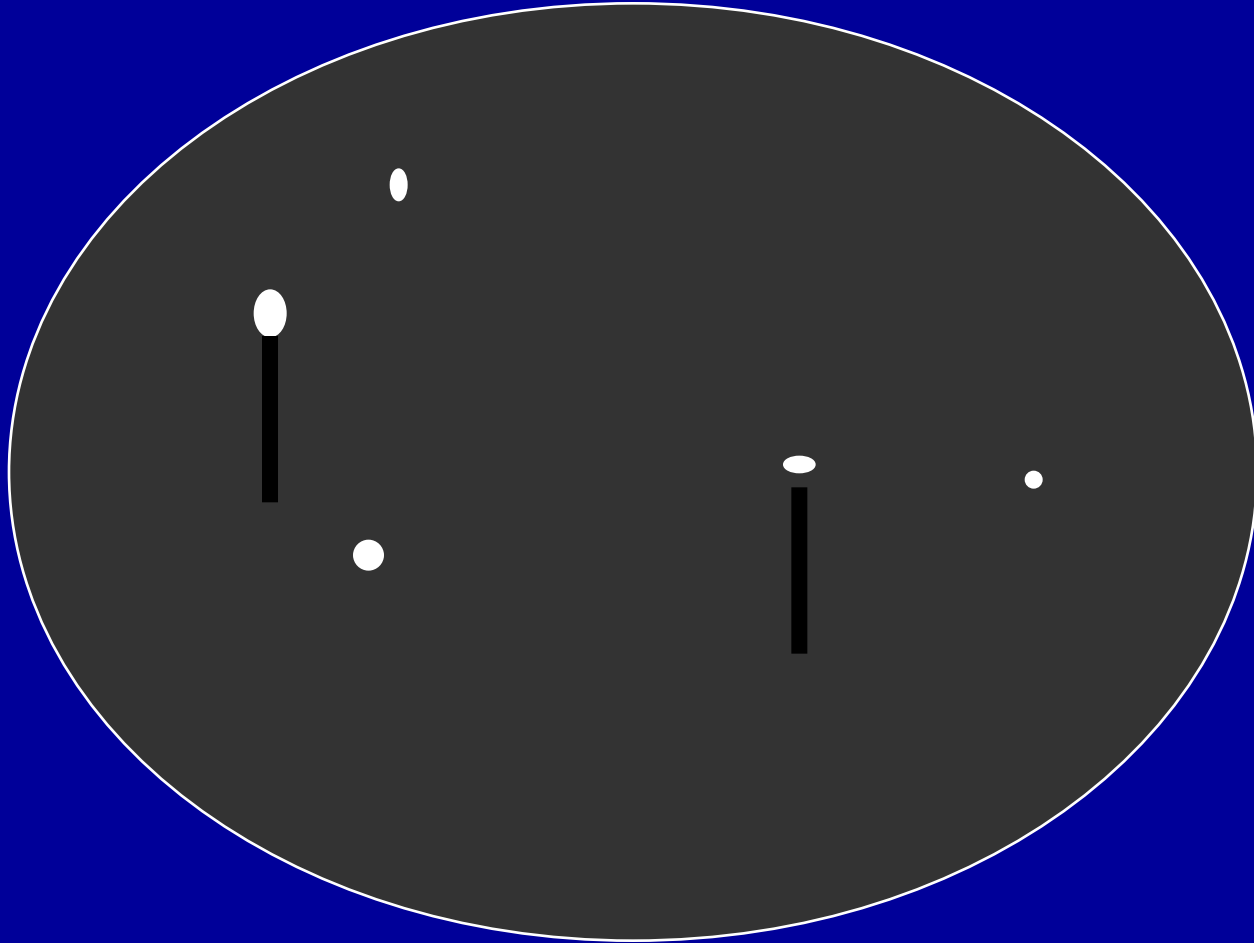
Malignant lymph nodes.



Malignant lymph nodes.

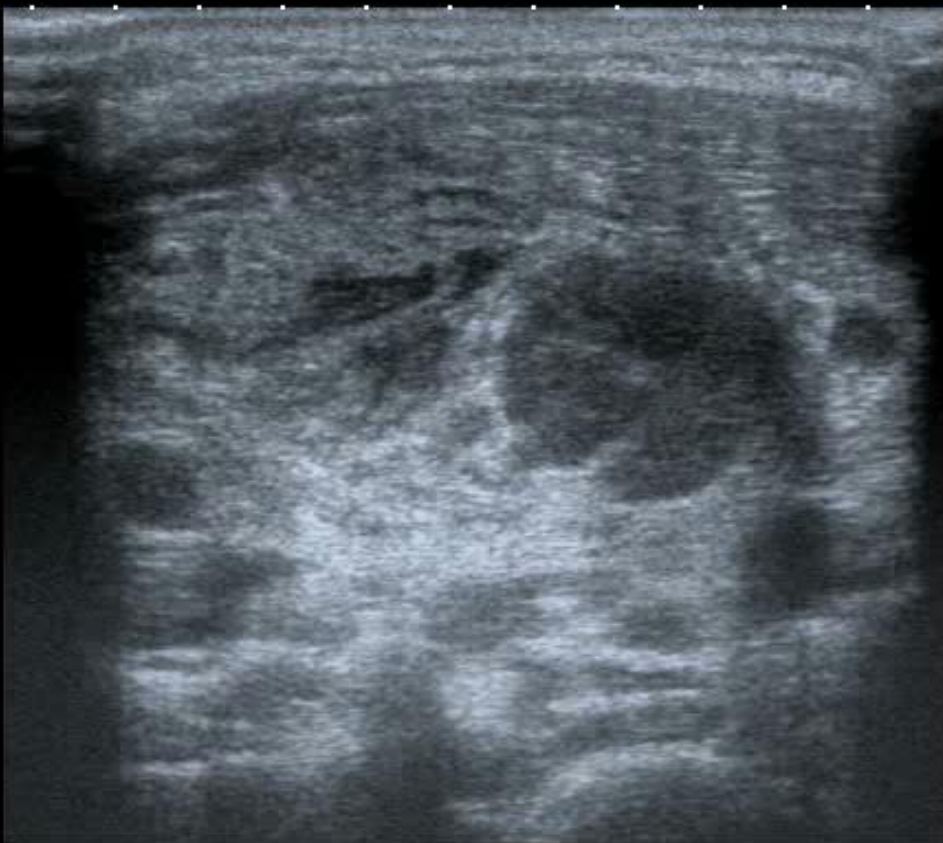

Malignant lymph nodes.





0 T



MI:1.6
2DG
80
DR
70

12L5
T9.0

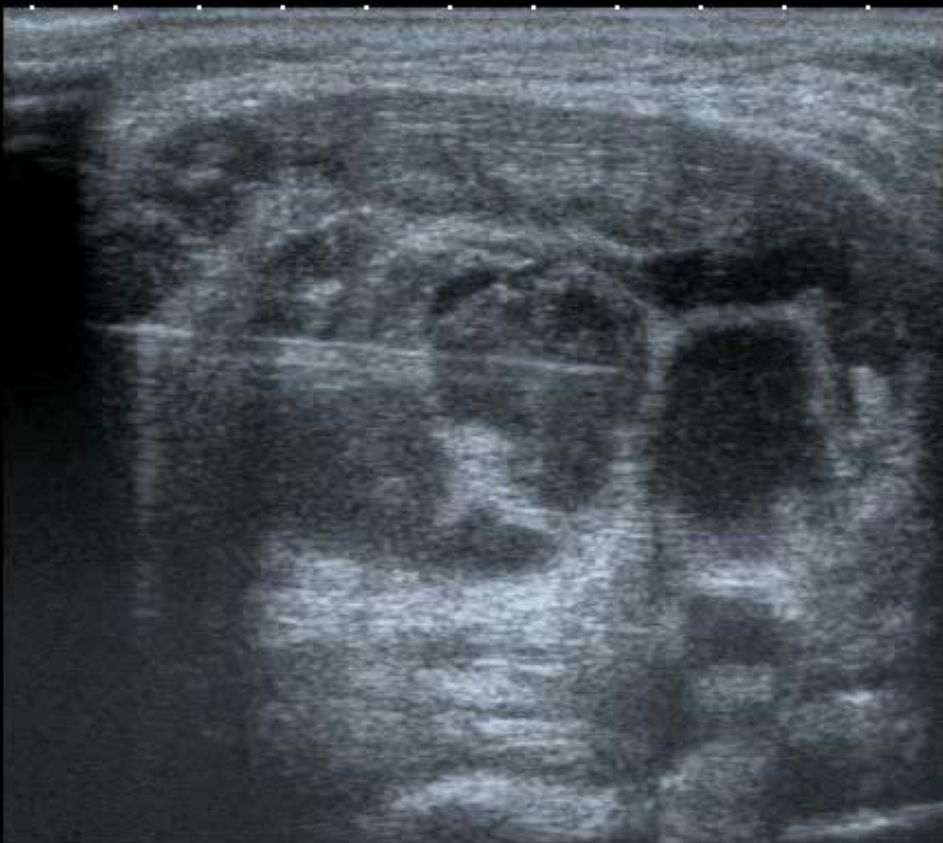4

27 fps





0 ♦ T



MI:1.6
2DG
80
DR
70

12L5
T9.0

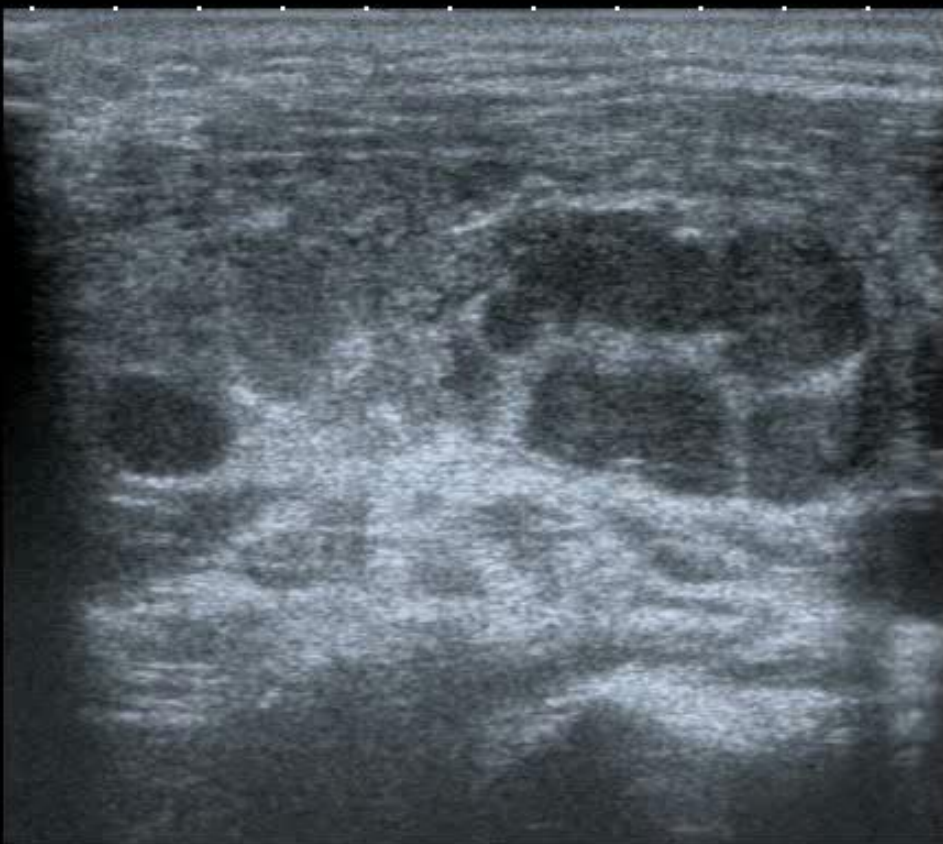
4 ♦

27 fps





0 ◆ T



2 ◆

4 ◆

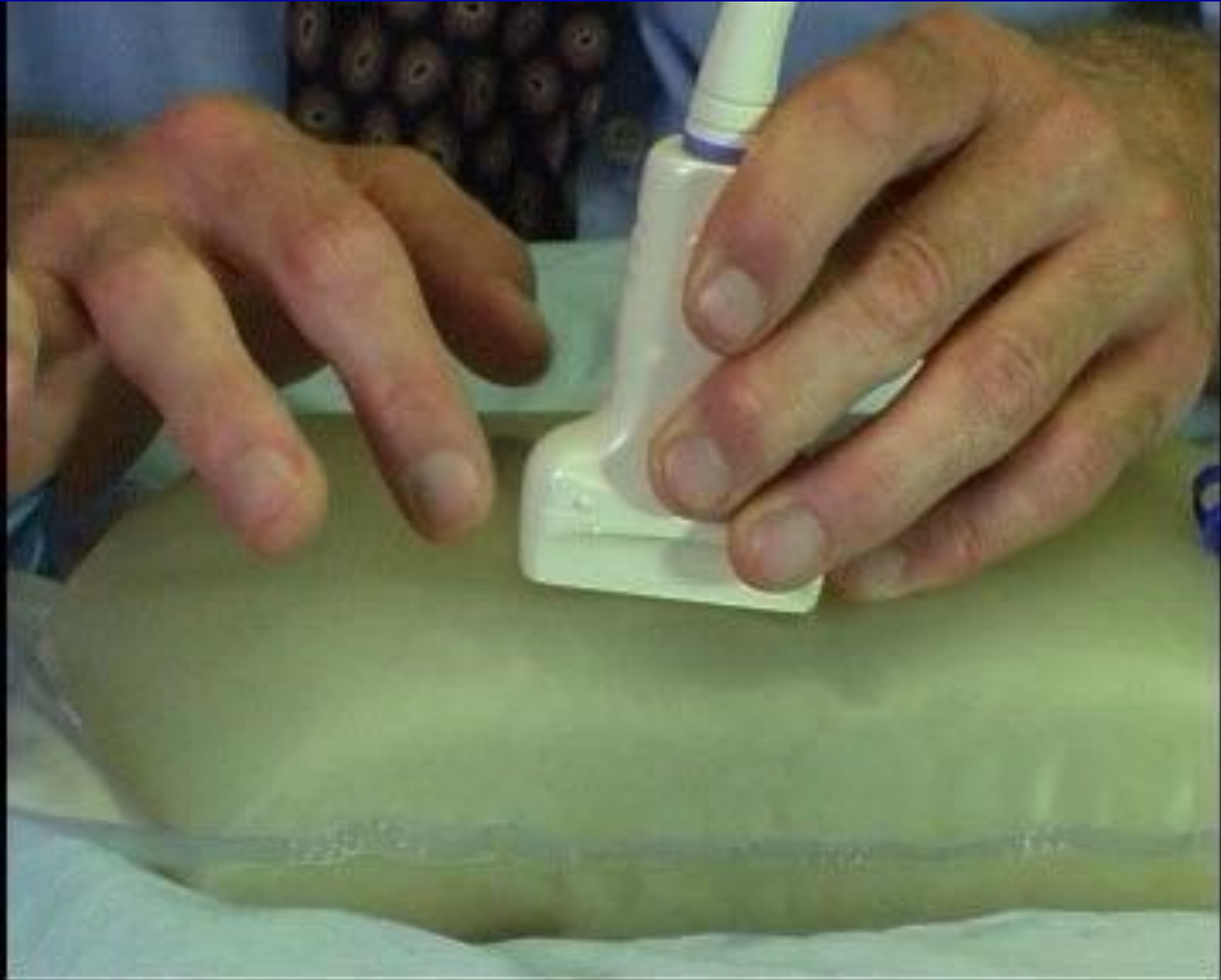MI:1.6
2DG
80
DR
70

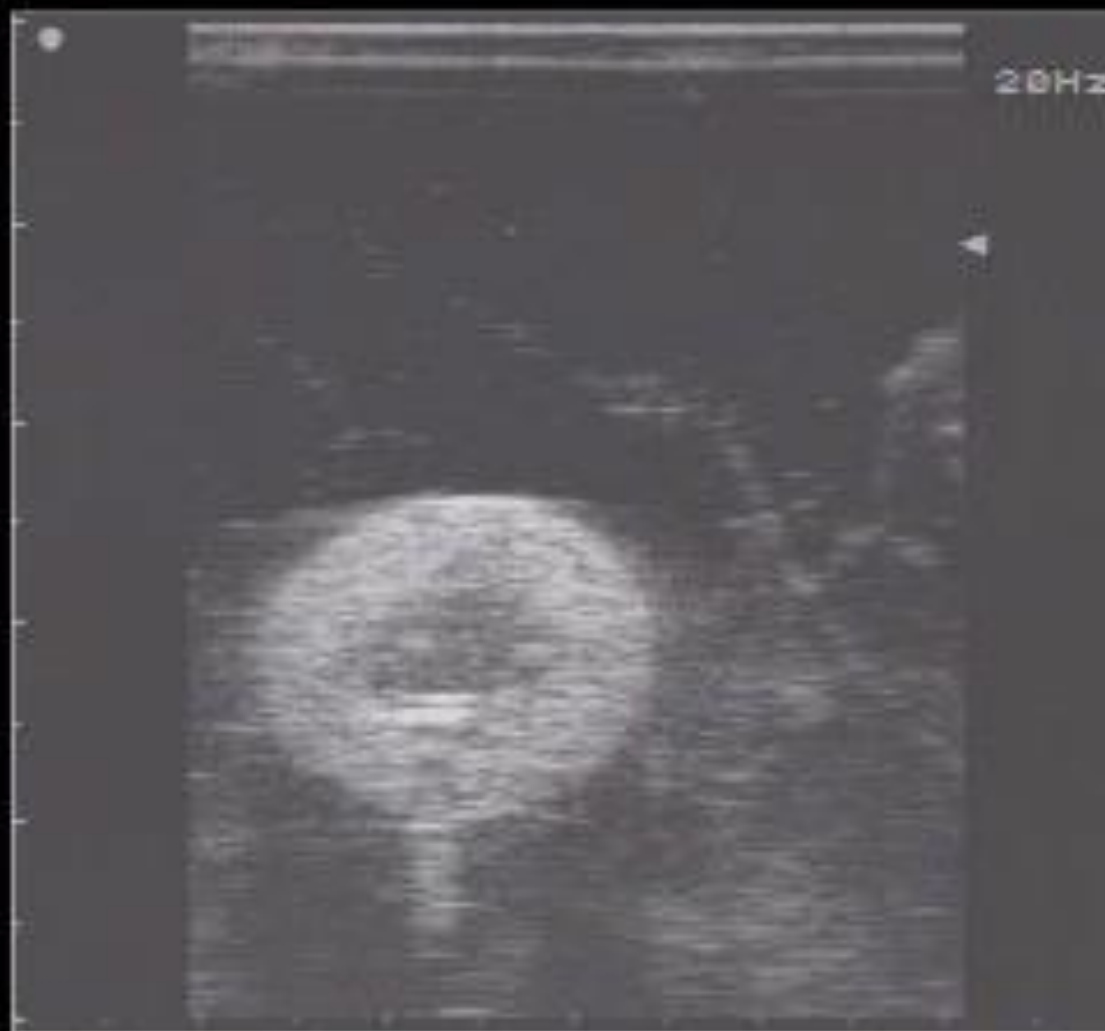12L5
T9.0
27 fps



Fine Needle Aspiration.

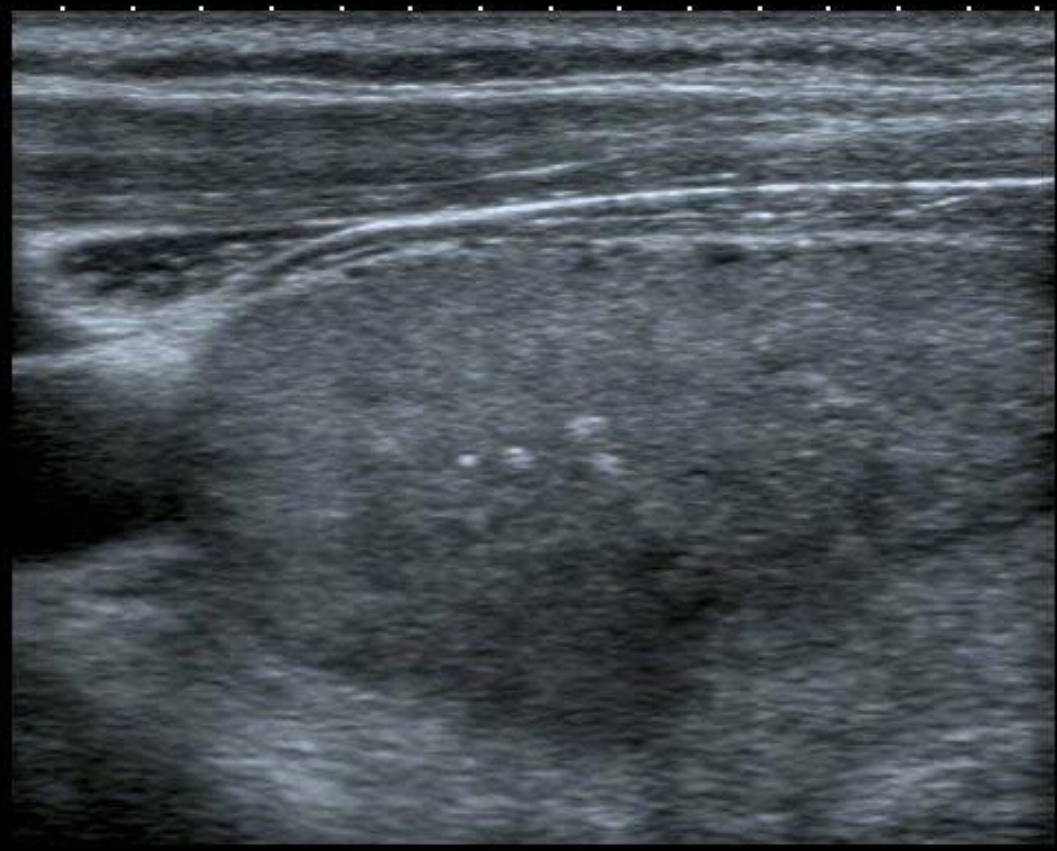
- No aspiration technique.
- Spinal needle.
- Deep lesions.
- Haemorrhage.







- 0 ◆
- 1 ◆▶
- 2 ◆
- 3 ◆



T

MI:1.4
2DG
80
DR
65

14L7
diffT13.0
25 fps

IP4

HDD:63% Free



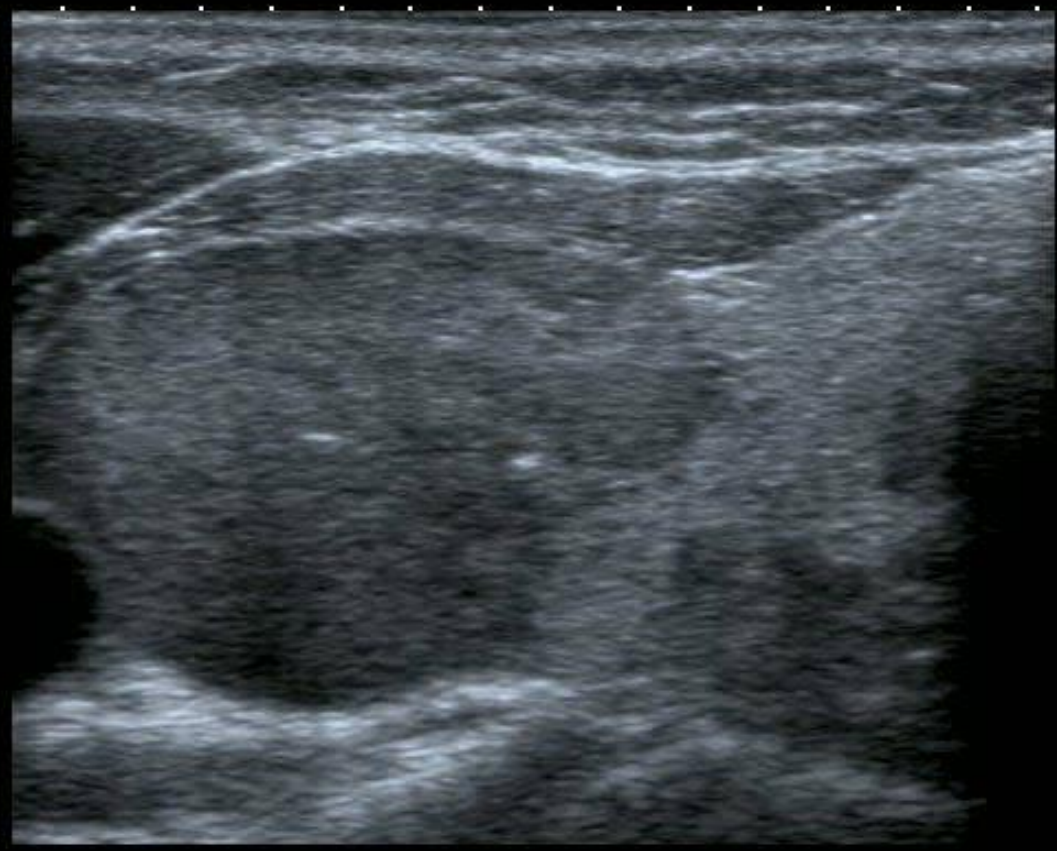


0 ◆

1 ◆▶

2 ◆

3 ◆



T


MI:1.4
2DG
80
DR
65

14L7
diffT13.0



25 fps



IP4



HDD:63% Free





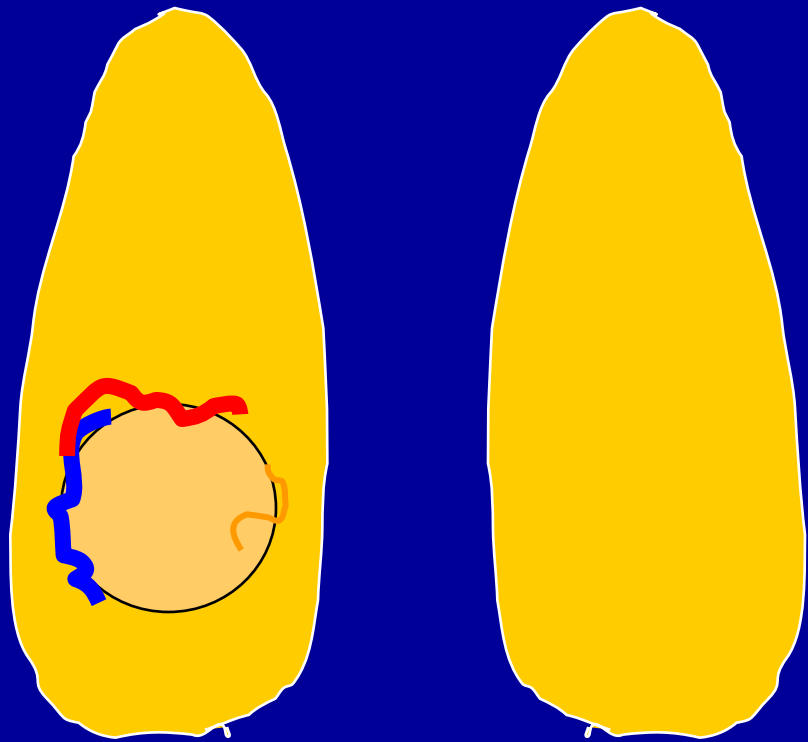
Signs?



























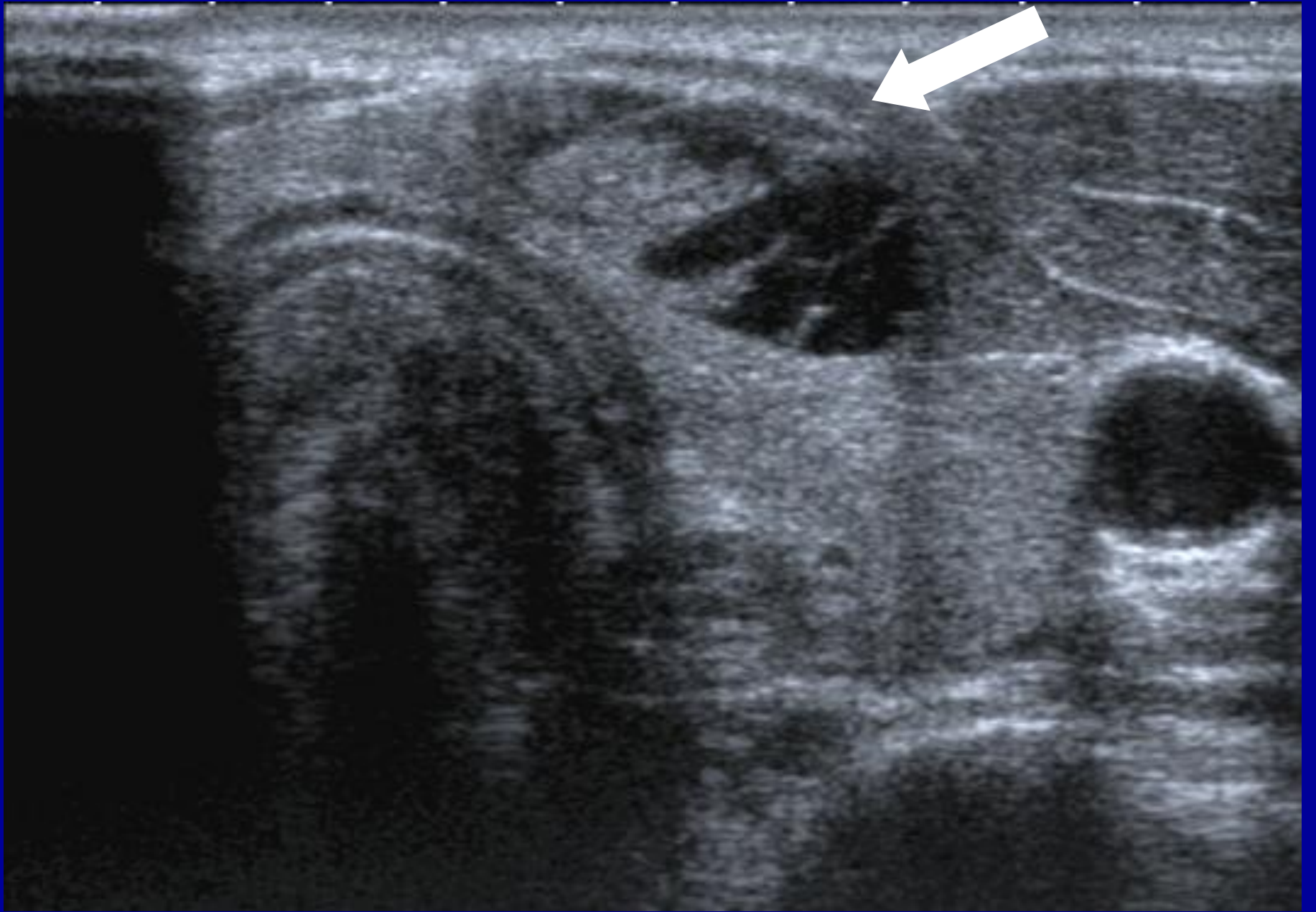


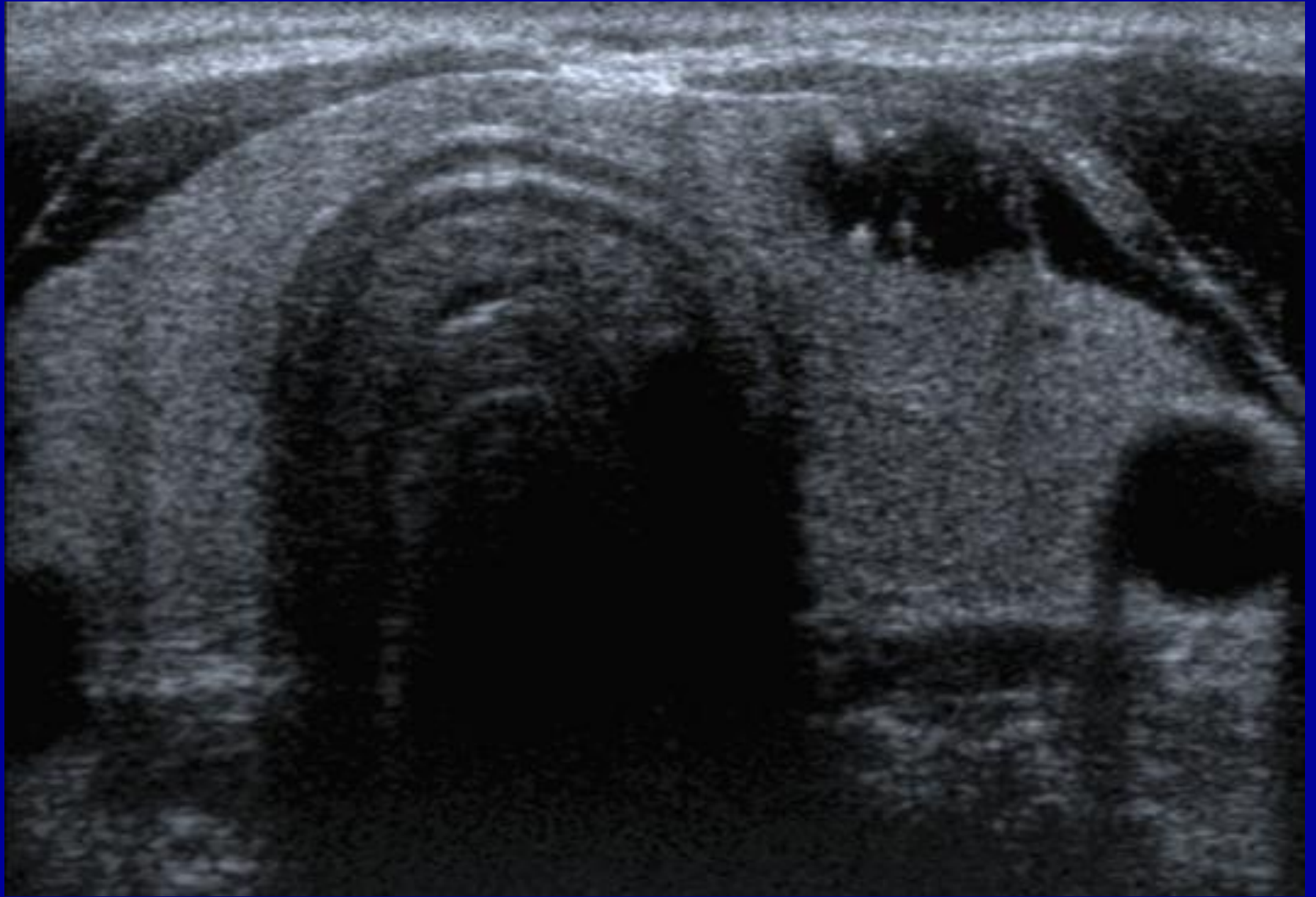


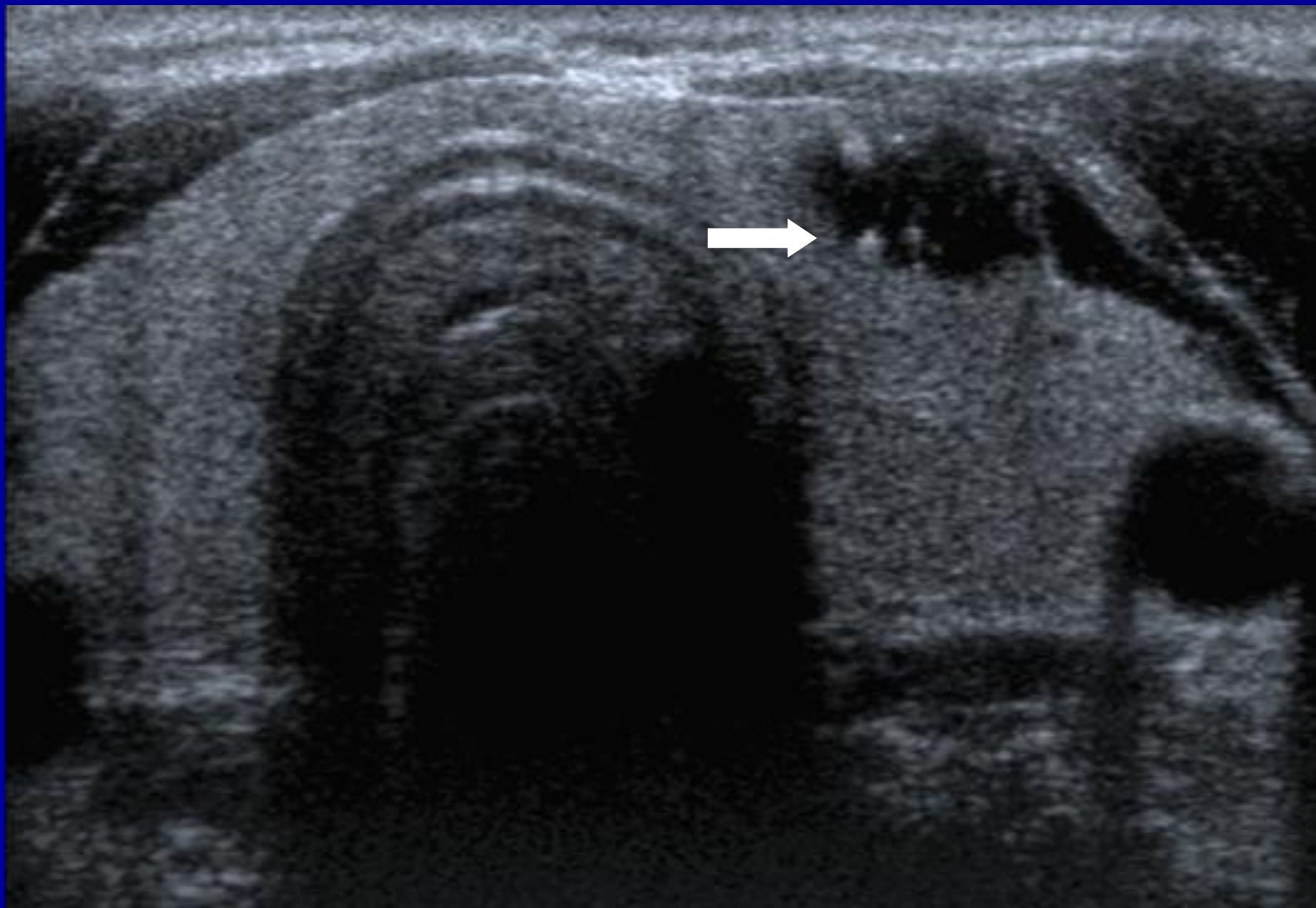


In practise?

- Knowledge
- Hand/eye coordination.
- Needle/probe.
- Needle/monitor.



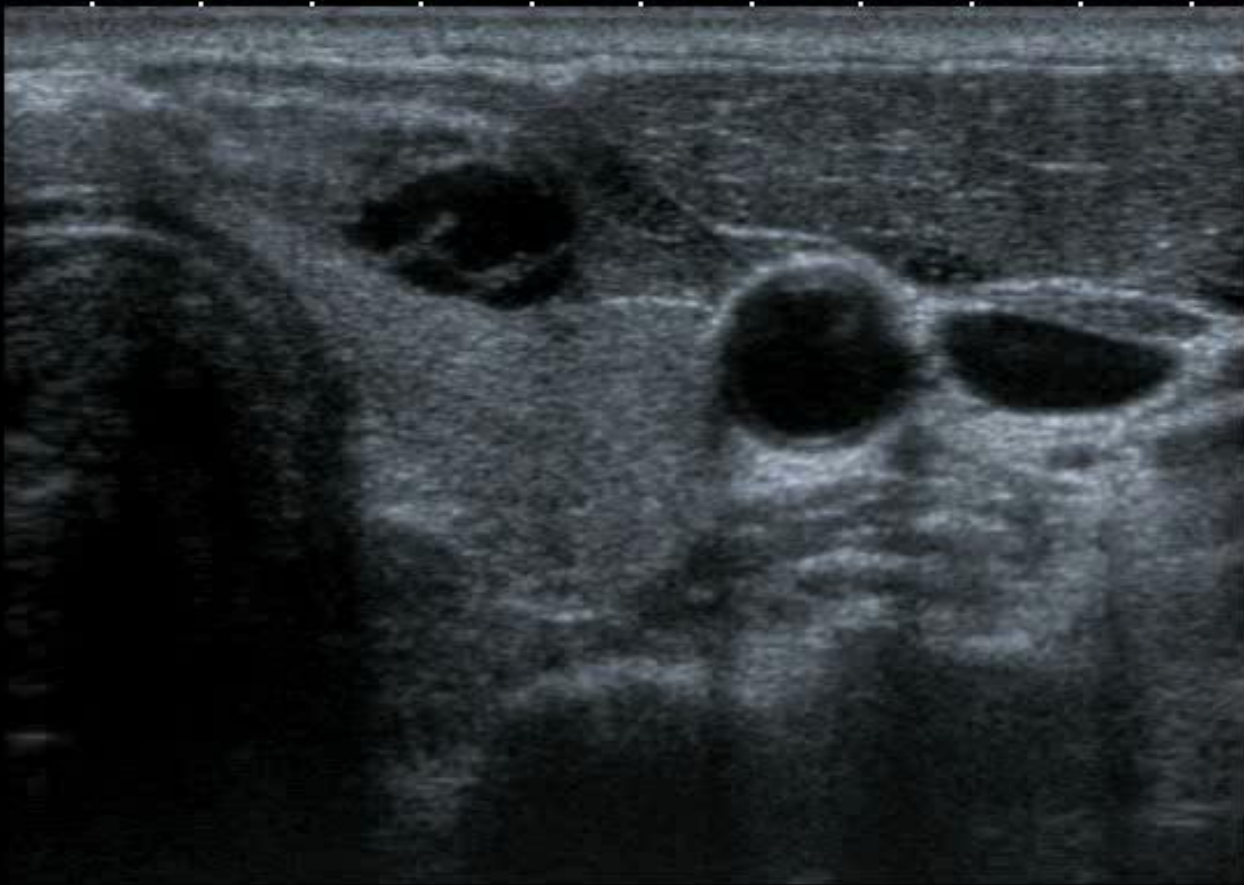




T
0
1
2
3
4

12L5
T9.0

33 fps



MI:1.6
2DG
93
DR
70








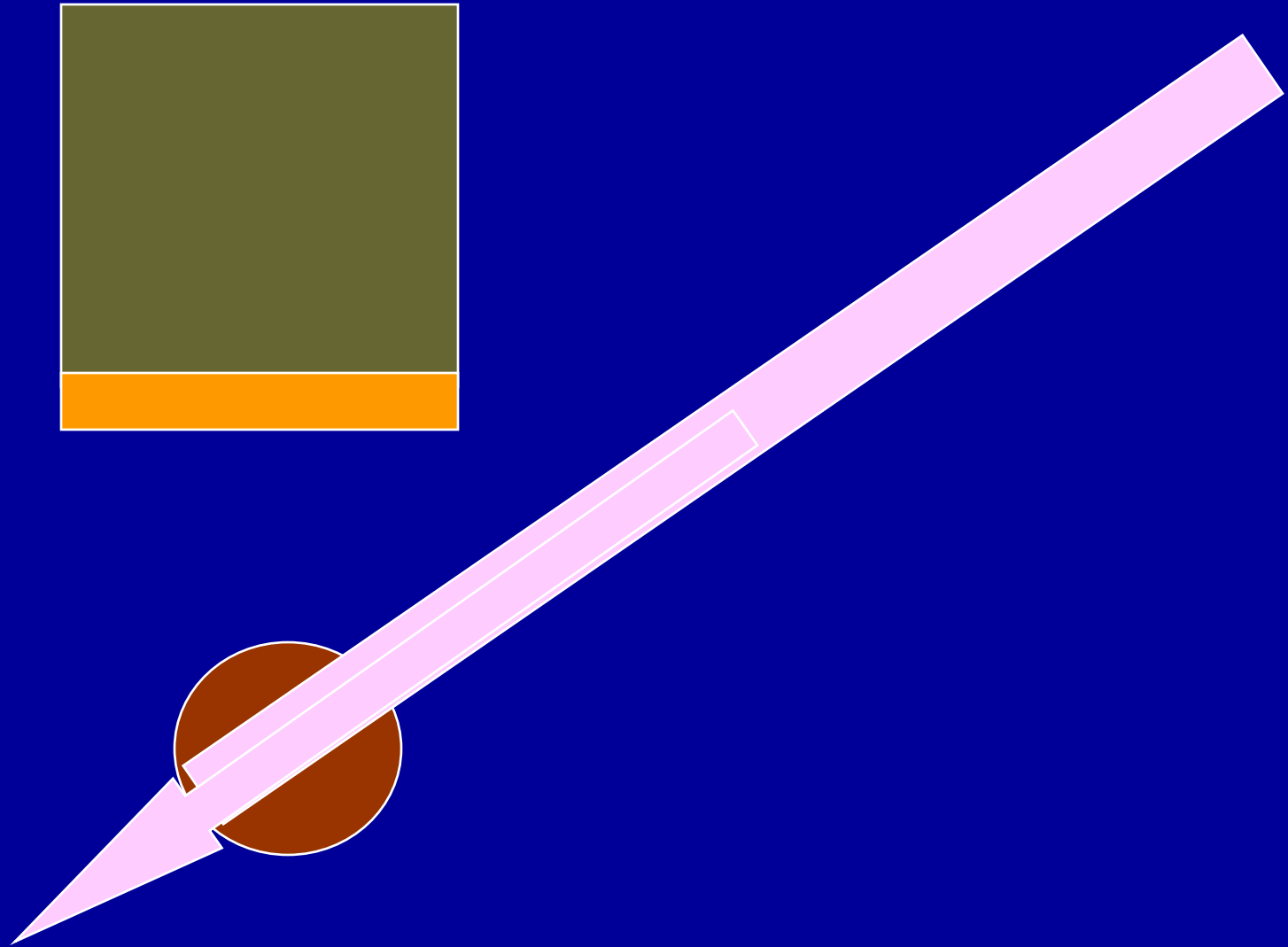
www.headandneckultrasound.co.uk

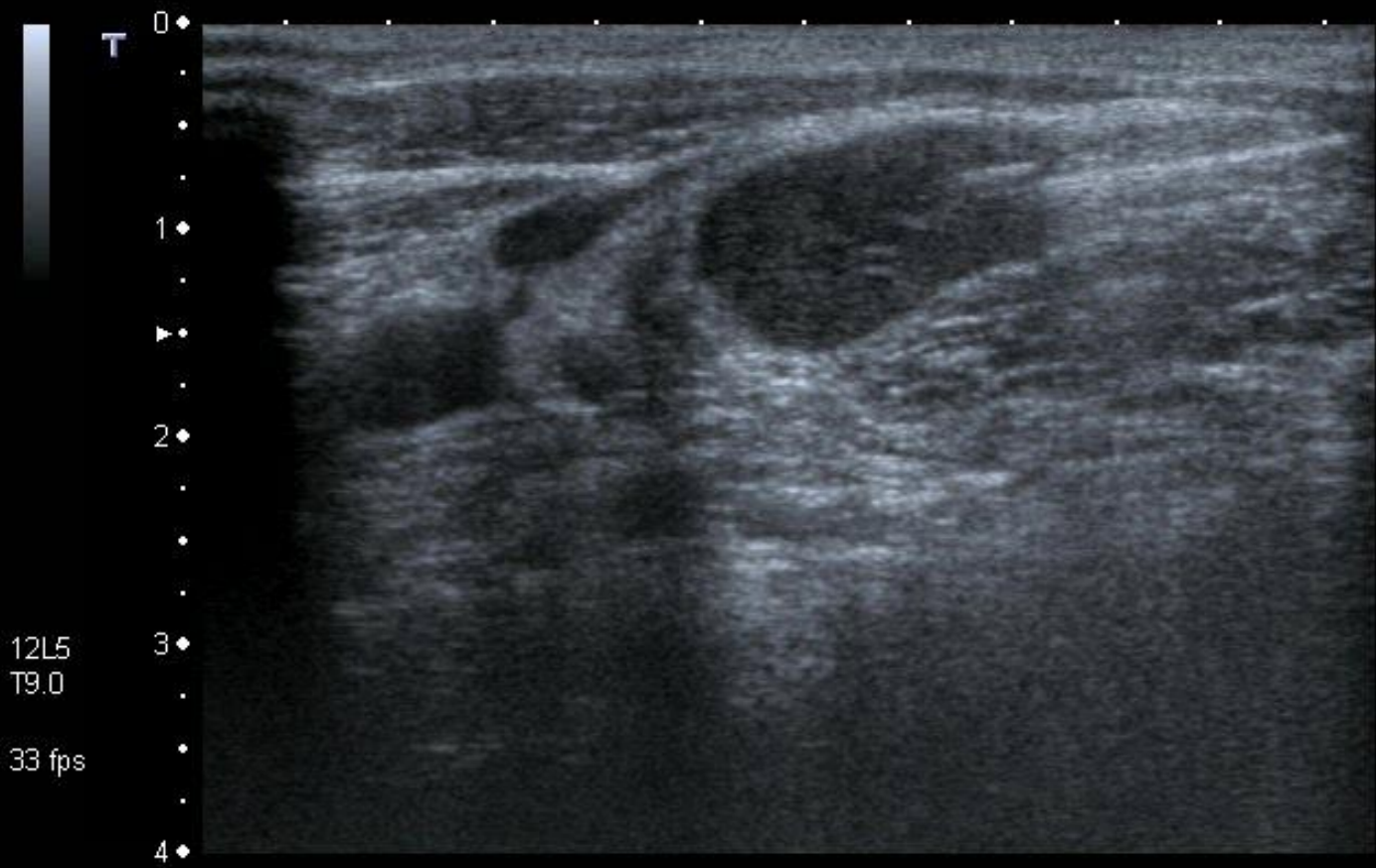
Core Biopsy.

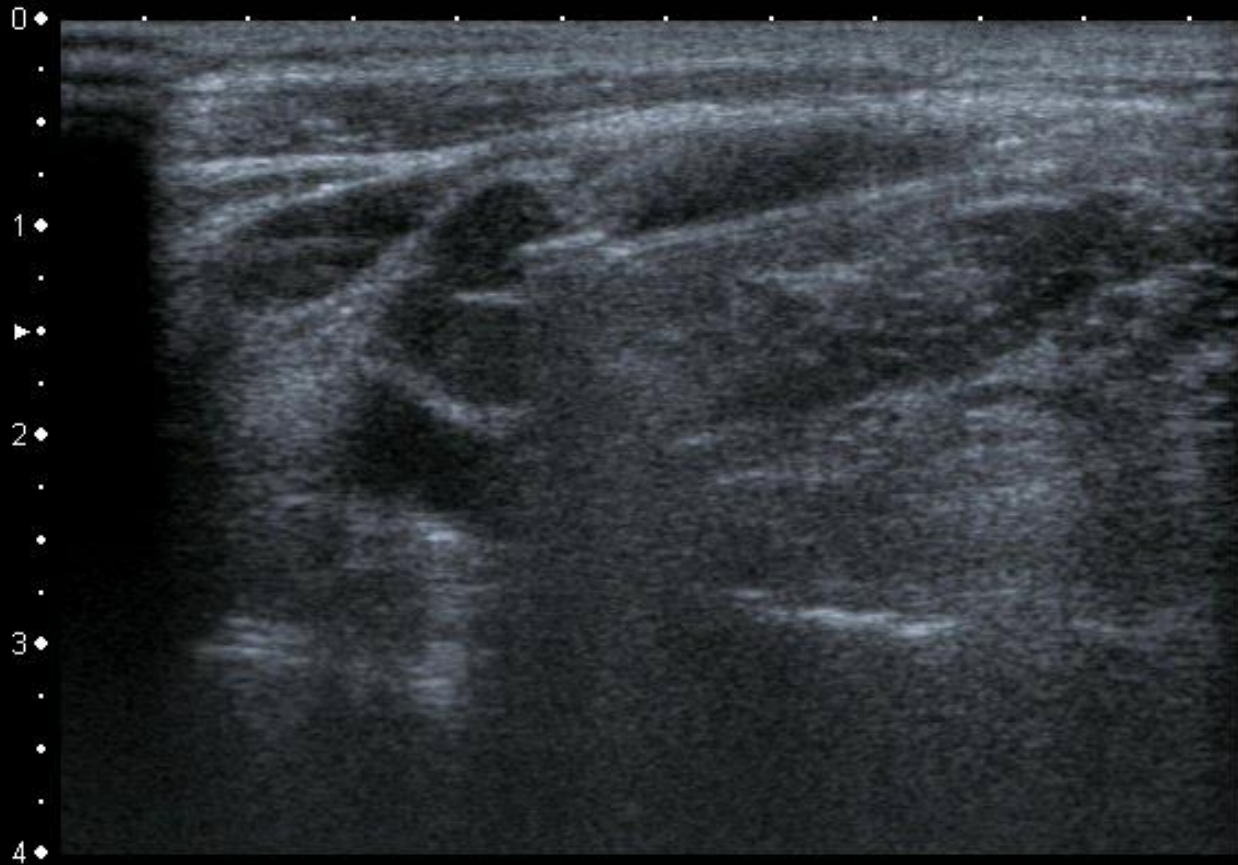
- Non Advancing needle.









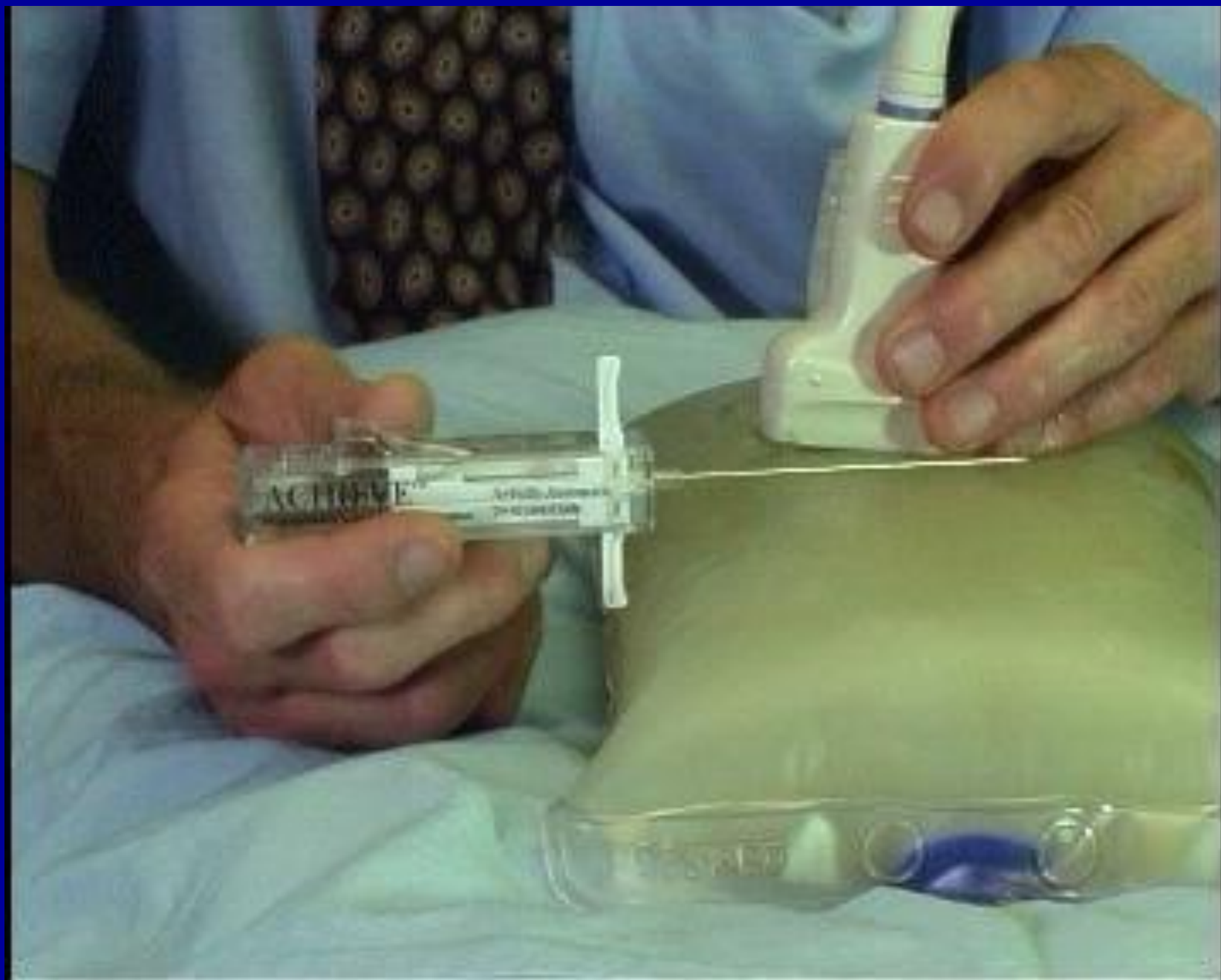

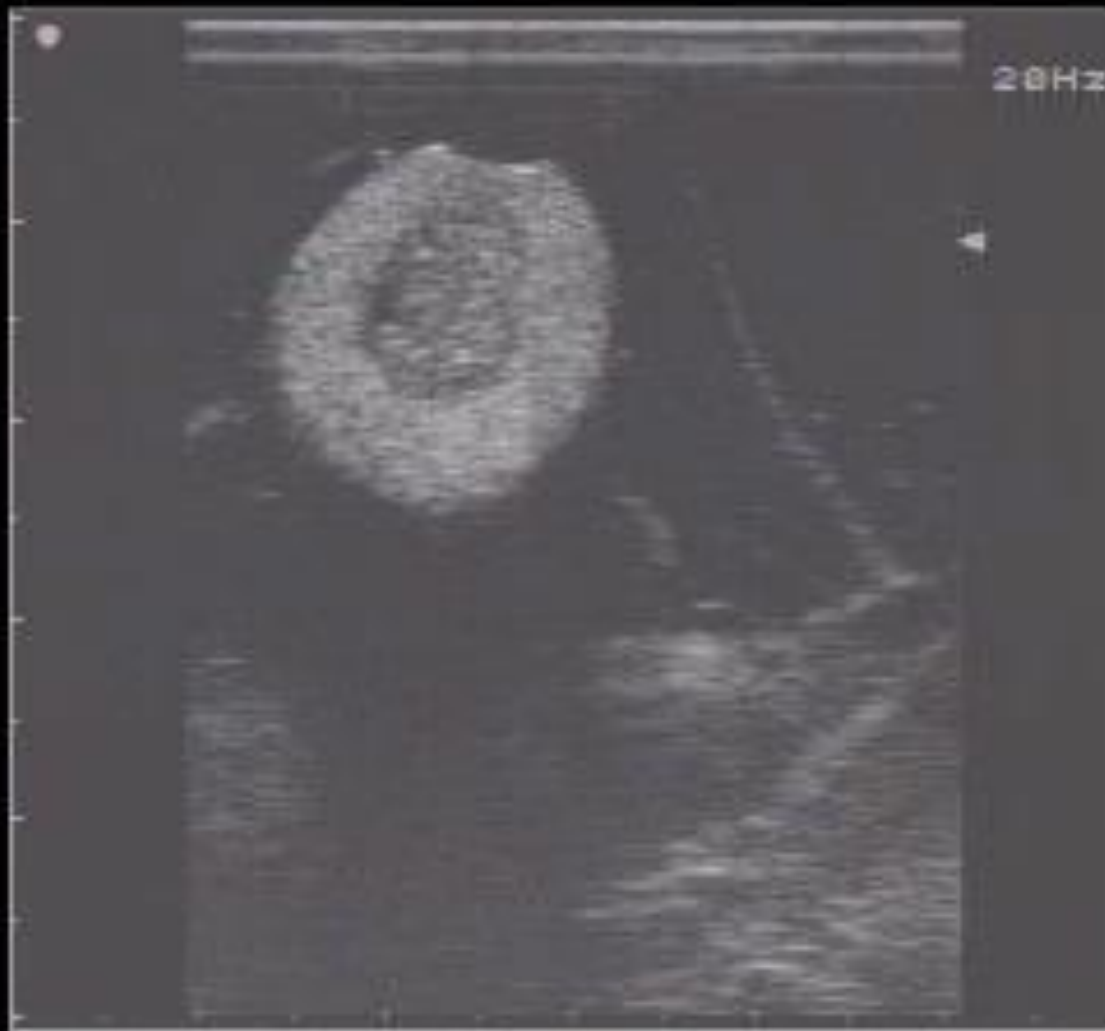0 ◆
.
1 ◆
▶
2 ◆
.
3 ◆
.
4 ◆

MI:1.6
2DG
80
DR
70

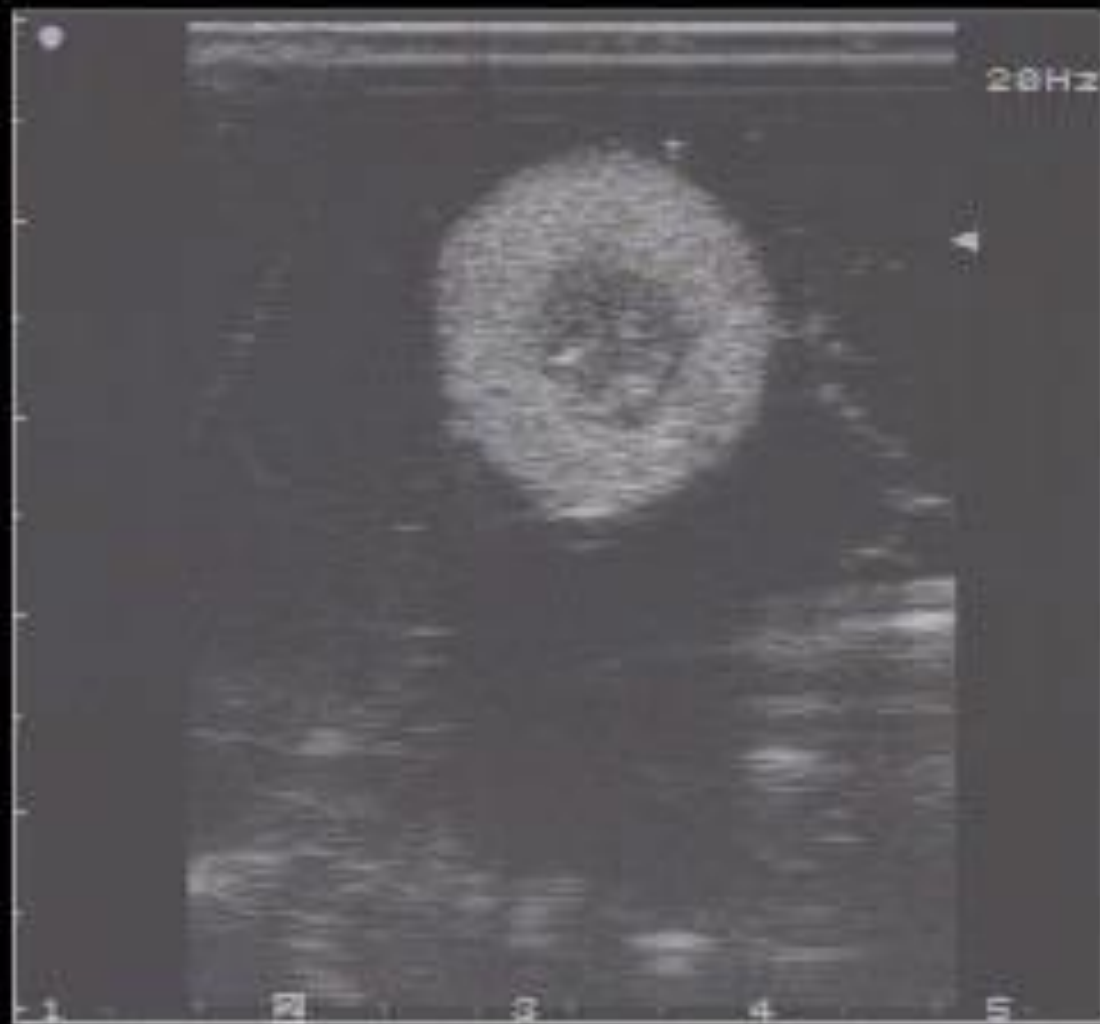12L5
T9.0
33 fps







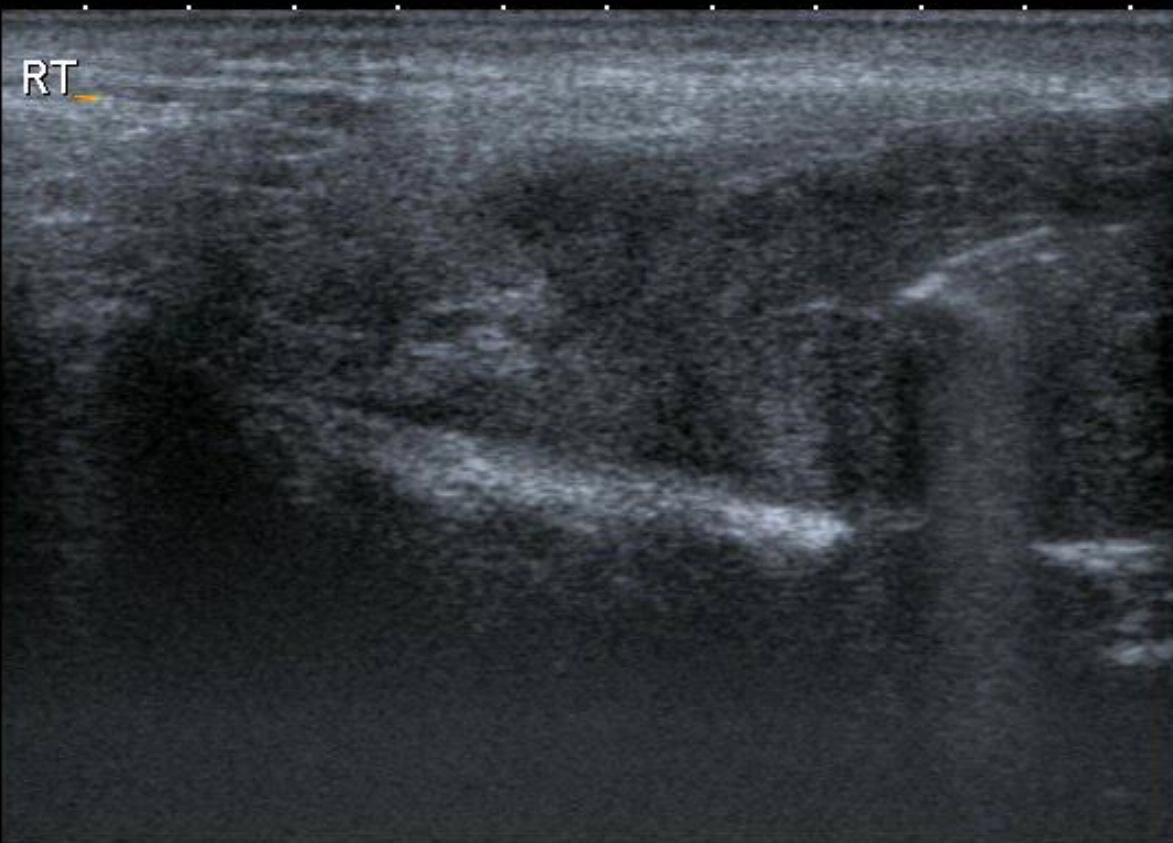
Positioning : see the gate.



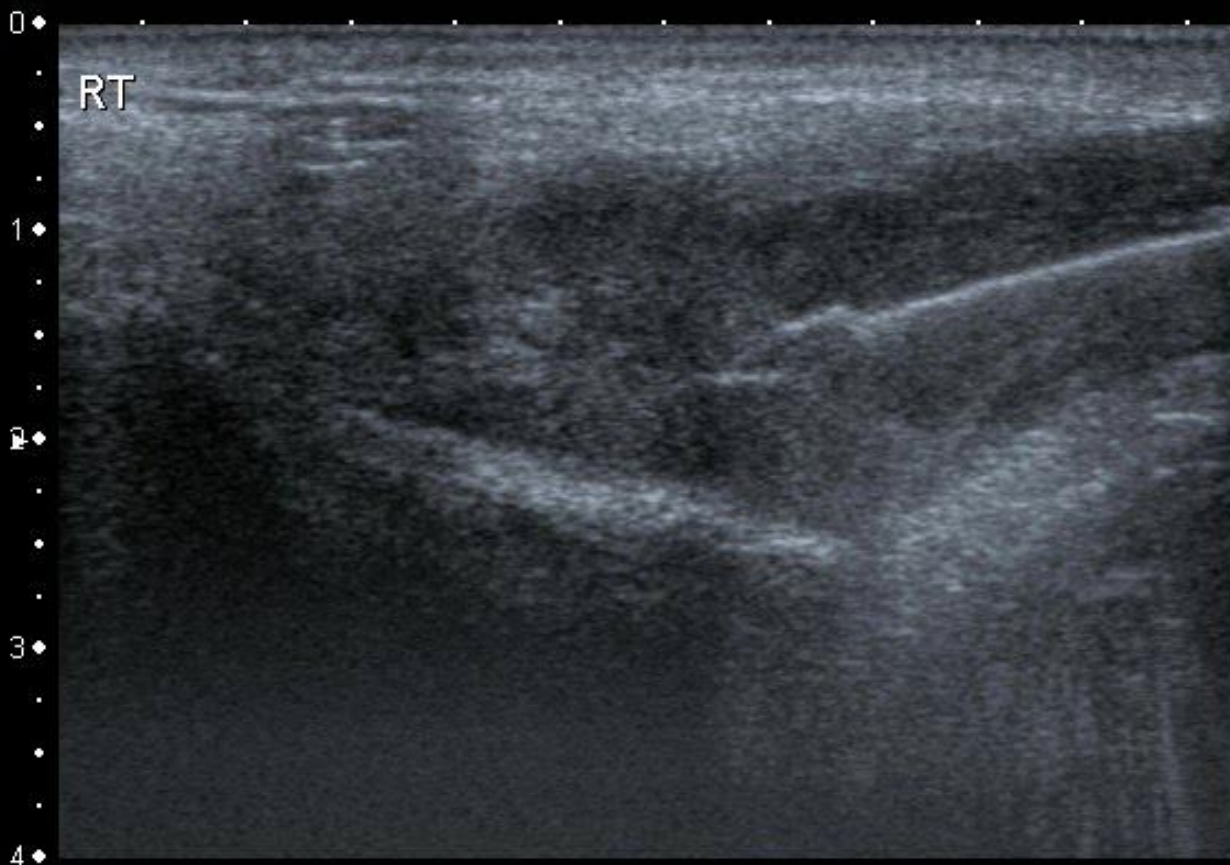T
0
1
2
3
4

12L5
T9.0

37 fps



MI:1.6
2DG
85
DR
70



MI:1.6
2DG
85
DR
70

12L5
T9.0
37 fps

0
1
2
3
4



Core Biopsy.

- Plan approach – **always** short axis.
- Anaesthesia under ultrasound control.
- Practice the click.
- Catch the needle ,see the gate.
- Flat surface – parallelism.
- Position the gate – click coming.
- Smooth and easy!





www.headandneckultrasound.co.uk